

Management of prosthetic joint infections. Clinical practice guidelines by the Spanish Society of Infectious Diseases and Clinical Microbiology (SEIMC)

Javier Ariza Cardenal ^a, Javier Cobo Reinoso ^{b,*}, Josu Baraia-Etxaburu Artetxe ^c, Natividad de Benito Hernández ^d, Guillermo Bori Tuneu ^e, Javier Cabo ^f, Pablo Corona Pérez-Cardona ^g, Jaime Esteban Moreno ^h, Juan Pablo Horcajada Gallego ⁱ, Jaime Lora-Tamayo Morillo-Velarde ^j, Óscar Murillo Rubio ^k, Julián Palomino Nicás ^l, Jorge Parra Ruiz ^m, Carlos Pigrau Serrallach ⁿ, José Luis del Pozo León ^o, Melchor Riera Jaume ^p, Dolores Rodríguez Pardo ^q, Mar Sánchez-Somolinos ^r, Álex Soriano Viladomiu ^s, María Dolores del Toro López ^t y Basilio de la Torre Escuredo ^u

^a *Coordinador, Servicio de Enfermedades Infecciosas, Hospital Universitari de Bellvitge, IDIBELL, Barcelona*

^b *Coordinador, Servicio de Enfermedades Infecciosas, Hospital Universitario Ramón y Cajal, IRYCIS, Madrid*

^c *Servicio de Enfermedades Infecciosas, Hospital Universitario de Basurto, Bilbao*

^d *Unidad de Enfermedades Infecciosas, Hospital de la Santa Creu i Sant Pau, Barcelona*

^e *Servicio de Cirugía Ortopédica y Traumatología, Hospital Clínic, Barcelona*

^f *Servicio de Cirugía Ortopédica y Traumatología, Hospital Universitari de Bellvitge, Barcelona*

^g *Servicio de Cirugía Ortopédica y Traumatología, Hospital Universitari Vall d'Hebron, Barcelona*

^h *Departamento de Microbiología Clínica. Hospital Universitario Fundación Jiménez Díaz, Madrid*

ⁱ *Servicio de Enfermedades Infecciosas, Hospital del Mar, IMIM, Barcelona*

^j *Unidad de Enfermedades Infecciosas, Hospital Universitario 12 de Octubre, Madrid*

^k *Servicio de Enfermedades Infecciosas, Hospital Universitari de Bellvitge, Barcelona*

^l *Unidad Clínica de Enfermedades Infecciosas, Microbiología y Medicina Preventiva, Hospital Universitario Virgen del Rocío, Sevilla*

^m *Servicio de Enfermedades Infecciosas, Hospital Clínico San Cecilio, Granada*

ⁿ *Servicio de Enfermedades Infecciosas, Hospital Universitari Vall d'Hebron, Barcelona*

^o *Área de Enfermedades Infecciosas y Microbiología Clínica, Clínica Universitaria de Navarra, Pamplona*

^p *Servicio de Medicina Interna-Infecciosas, Hospital Son Espases, Palma de Mallorca*

^q *Servicio de Enfermedades Infecciosas, Hospital Universitari Vall d'Hebron, Barcelona*

^r *Servicio de Microbiología y Enfermedades Infecciosas, Hospital General Universitario Gregorio Marañón, Madrid*

^s *Servicio de Enfermedades Infecciosas, Hospital Clínic, Barcelona*

^t *Unidad Clínica de Enfermedades Infecciosas, Microbiología y Medicina Preventiva, Hospital Universitario Virgen Macarena, Sevilla*

^u *Servicio de Cirugía Ortopédica y Traumatología, Hospital Universitario Ramón y Cajal, Madrid*

On behalf of the Spanish Network for the Study of Infectious Diseases and the Spanish Society of Infectious Diseases and Clinical Microbiology (SEIMC, Sociedad Española de Enfermedades Infecciosas y Microbiología Clínica) along with expert orthopedic surgeons from the Spanish Group of Septic Pathology of the Locomotive System (GEPsAL, Grupo de Estudio de Patología Séptica del Aparato Locomotor).

ABSTRACT

The incidence of prosthetic joint infection (PJI) is expected to increase in the years to come. PJI pose serious consequences for patients and high costs for the health system. The complexity of these infections make it necessary to organize the vast quantity of information published in the last years to help professionals of orthopaedic surgery, infectious disease specialists, internal medicine physicians, microbiologists, and all other health professionals responsible for the everyday management of patients with PJI. The present guidelines have been developed from a flowchart that includes the different medical-surgical strategies available to treat patients with PJI. The authors selected clinically relevant questions and then reviewed the available literature in order to give recommendations according to a predetermined degree of scientific evidence. The absence of randomized-controlled trials is remarkable; therefore, recommendations are mainly based on observational studies and data from animal studies. Before its final publication, the manuscript was made available online so that all members of the Spanish Society of Infectious Diseases and Clinical Microbiology (SEIMC) were able to read it and make comments and suggestions.

ARTICLE INFORMATION

Keywords:

Prosthetic joint infection

Arthroplasty infection

Tratamiento de las infecciones de prótesis articulares. Guía clínica práctica de la Sociedad Española de Enfermedades Infecciosas y Microbiología Clínica (SEIMC)

RESUMEN

Se prevé un incremento de la incidencia de infección de las prótesis articulares (IPA) en los próximos años. Las IPA plantean graves consecuencias para los pacientes y un alto coste para el sistema sanitario. La complejidad de estas infecciones hace que sea necesario organizar la inmensa cantidad de información publicada en los últimos años para ayudar a los cirujanos ortopedas, infectólogos, internistas, microbiólogos y otros especialistas involucrados en el cuidado diario de los pacientes con IPA. Estas guías se han desarrollado partiendo de un algoritmo que incluye las diferentes estrategias médico-quirúrgicas disponibles para tratar a los pacientes con IPA. Los autores seleccionaron las preguntas clínicamente relevantes y revisaron la bibliografía disponible con el fin de proporcionar recomendaciones de acuerdo con un grado de evidencia científica determinada. Resulta llamativa la ausencia de ensayos clínicos

aleatorizados, por lo que las recomendaciones están basadas principalmente en estudios observacionales y datos de estudios realizados en animales de experimentación. Antes de su publicación el manuscrito estuvo abierto a comentarios y sugerencias de los miembros de la Sociedad Española de Enfermedades Infecciosas y Microbiología Clínica (SEIMC).

Palabras clave:

Infección de prótesis articular

Infección de artroplastia

* Corresponding author.

e-mail: javier.cobo@salud.madrid.org

Rationale for these clinical guidelines

The incidence of prosthetic joint infection (PJI) is expected to increase in the years to come^{1,2}. The occurrence of a PJI dramatically raises the economic costs of an arthroplasty and it is also catastrophic for the patient²⁻⁵. The algorithm proposed by Zimmerli represents a notable step forward in the management of these infections, and subsequent publications have confirmed its clinical usefulness⁶⁻⁹.

The vast quantities of data on PJI published in recent years, along with the inherent complexity of these infections, make it necessary to organize and analyse the available information. The French and Italian guidelines were published more than five years ago^{10,11} and, while the Infectious Diseases Society of America (IDSA) guidelines are more recent¹², they do not deal with many important aspects of antimicrobial therapy¹³.

In Spain, a consolidated group of research on PJI, including centers in the Spanish Network for Research in Infectious Diseases (REIPI, <http://reipi.org>), has generated an impressive body of scientific knowledge on the subject. The idea for preparing the clinical practice guidelines presented here originated in this group, in collaboration with expert orthopaedic surgeons from the Spanish Group of Septic Pathology of the Locomotive System (GEPAL, Grupo de Estudio de Patología Séptica del Aparato Locomotor) and the Spanish Society of Orthopaedic Surgery and Traumatology (SECOT, Sociedad Española de Cirugía Ortopédica y Traumatología).

Scope

The present guidelines focus on the management of PJI by classifying all the possible therapeutic scenarios according to clinical presentation. The indications for the choice of a given surgical strategy and the correspondent antimicrobial therapy are specifically reviewed.

These guidelines are addressed to professionals of orthopaedic surgery, infectious disease specialists, internal medicine physicians, microbiologists, and all other health professionals responsible for the everyday management of patients with PJI. They may also be useful for other specialists who participate less frequently in the treatment of these patients, such as geriatricians, rheumatologists, physical therapy specialists, and plastic surgeons.

Methods

Two authors (JA, JC), both infectious disease specialists, coordinated the contributions of the other authors (infectious disease specialists, internal medicine physicians, clinical microbiologists and orthopaedic surgeons). The recommendations of the Spanish National Health System Manual for the Writing of Practice Guidelines (<http://www.guiasalud.es/emanuales/elaboracion/index-02.html>) were followed, as well as the regulations of the Spanish Society of Clinical Microbiology and Infectious Diseases (SEIMC, Sociedad Española de Enfermedades Infecciosas y Microbiología Clínica) and the *Agree collaboration recommendations* (http://www.guiasalud.es/contenidos/documentos/Guias_Practica_Clinica/Spanish-AGREE-II.pdf) regarding the methodological quality of practice guidelines.

A “choice chart” was set up for the creation of these guidelines, including five possible clinical scenarios (fig. 1) which raised several clinical questions of interest. Each scenario was assigned to a working team of authors, who reviewed all the literature published since 1970 in order to answer these questions with a predetermined degree of scientific evidence (Table 1)¹⁴. The manuscript was reviewed by all authors at various stages. The more controversial aspects were debated and the final composition was agreed at an *ad hoc* meeting. All the authors approved the final version of the guidelines. Before its final publication, the manuscript was made available online so that all SEIMC members were able to read it and make comments and suggestions.

Initial assessment of a patient with PJI

What are the goals of treatment?

The aims of the treatment of a patient with PJI are to eradicate the infection, alleviate the pain and, at the same time, restore the joint’s function¹⁵. This makes PJI different from other infections in which the eradication of the infection alone may be sufficient for evaluating a given therapeutic strategy. In the case of PJI, all three goals must be considered in combination, since sometimes achieving one of these targets (i.e., eradication of the infection) may interfere with another (i.e., achieving a satisfactory functional outcome). This situation increases the complexity of the management of these patients, has a deep impact on the therapeutic decisions, and makes the interpretation of the literature difficult, since there is no standardized definition of therapeutic success¹⁶.

What should the care of patients with PJI involve?

Given the complexity of PJI and other types of bone and joint infection, these patients should be attended at multidisciplinary units staffed by orthopaedic surgeons, infectious disease specialists, microbiologists, plastic surgeons, physiotherapists and physical therapy specialists, as well as specifically trained nurses¹⁷⁻¹⁹. A specialized microbiology laboratory must also be available.

RECOMMENDATION

1. Due to the complexity of patients with PJI, they should be attended at multidisciplinary units (C-III).

What are the medical and surgical options for patients with PJI?

The management of patients with PJI often requires the removal of the prosthesis in order to eradicate the infection. This must be followed, if possible, by the insertion of a new arthroplasty. In some acute infections, however, retention of the prosthesis may be attempted by means of an exhaustive surgical debridement and prolonged antimicrobial therapy, which must be active against biofilm-embedded microorganisms. This strategy has been named DAIR (debridement, antibiotics, implant retention)²⁰. Some patients may be considered unsuitable for implant removal, either because they present with too many baseline conditions, or because a poor functional outcome is foreseen. In these patients, prolonged or indefinite antimicrobial therapy aiming to control the infection may be considered. This strategy is known as SAT (suppressive antimicrobial therapy)²¹.

Thus, the main medical and surgical strategies to be considered in a patient with PJI are:

- a) Attempted eradication with implant retention and antibiotics (DAIR).
- b) Attempted eradication with implant removal and antibiotics:
 - With prosthesis replacement (in a 1-step or a 2-step exchange procedure).
 - Without prosthesis replacement (arthrodesis or resection arthroplasty).
- c) Implant retention and long-term suppressive antibiotics (SAT), without attempted eradication.

What are the critical aspects influencing the choice of a particular medical and surgical strategy in a given patient?

The decision regarding the most appropriate medical and surgical strategy for a given patient should consider features of the prosthesis, the patient's baseline condition, his/her previous functional performance, life expectancy, desires and expectations, and also the surgical risk involved.

With regard to the prosthesis, the duration of the infection before initiating treatment is of paramount importance, because this is narrowly related with the biofilm's maturity and complexity, and thus with the difficulty of eradicating the infection. Two time points are used for evaluating the duration of the infection: the time when the prosthesis is placed (for post-surgical cases only), which is an objective measure; and the moment when the symptoms begin, which may be more difficult to establish.

The microorganisms responsible should be borne in mind as well as their susceptibility to antibiotics, especially those with a high activity against biofilm-embedded bacteria. The anatomical location of the PJI is another important factor, as well the condition of the surrounding soft tissue (e.g., the possible presence of sinus tracts, blisters, necrotic tissue) and periprosthetic bone (radiological signs of prosthetic loosening, bone stock).

Tsukayama's and Zimmerli's classifications of PJI are both helpful for guiding medical and surgical decisions in a given patient. These classifications are based on similar criteria, which take into account pathogenic aspects, the time of infection, and the diagnostic circumstances (Table 2)^{6,22}.

When is attempted eradication with implant retention (DAIR) indicated? What are the results?

Eradication of the infection with implant retention is an attractive and ambitious option, which may potentially save bone stock and avoid the need for more complex surgeries. However, this strategy runs a higher risk of failure (Table 3)^{20,22-41}. The available data are very heterogeneous regarding patients, etiologies and antimicrobial treatments, with success rates ranging from 18% to 94%. An optimized surgical and medical approach and good identification of the most appropriate candidates for this conservative management are key in order to maximize the likelihood of success and to avoid unnecessary surgeries²⁶.

This strategy has a higher chance of success in patients with acute infections, short duration of symptoms, a stable prosthesis and surrounding soft tissues in good condition, especially if antibiotics with good activity against biofilm-embedded bacteria can be used. Zimmerli's algorithm takes into account all these parameters, which have been shown to be relevant in the analysis of several retrospective cohorts^{6,28,42,43}. The observation of these criteria is helpful for identifying the patients with a greater likelihood of benefiting from prosthesis retention. However, the opposite situation (i.e., not meeting Zimmerli's criteria) does not unambiguously predict the failure of this strategy; as a result, strict application of the algorithm may deprive some patients of benefiting from this approach⁴²⁻⁴⁴. Due to the complexity of the condition of patients with PJI, tailored treatments and collegiate multidisciplinary decisions are advisable.

Although the majority of the studies have observed a higher likelihood of failure with longer duration of symptoms, the precise cut-off is variable^{23-26,30,31,33,34,38,39,43}. Indeed, in staphylococcal infections treated with β -lactams, Brandt *et al* found that the patients undergoing debridement delayed more than 48 hours had a worse prognosis²⁵. Subsequent studies using fluoroquinolone and rifampin combinations showed good results with longer periods of time^{26,40,43}. The 21-day limit of symptom duration suggested by Zimmerli *et al* is based on a clinical trial published in 1998 in which all patients included underwent debridement within this time period⁴⁵. In any case, caution is required when evaluating the importance of symptom duration, because it may be a surrogate parameter of clinical presentation and severity: acute cases in ill patients usually carry a worse prognosis, but precisely for this reason they may undergo debridement earlier^{20,31,36}. Equally, it is sometimes difficult to determine the precise moment when the symptoms began.

The concept of 'acute infection' includes both early post-surgical infections and haematogenous infections. The latter have a worse prognosis^{43,46}, but clinical diagnosis is usually straightforward^{6,22}. In the case of post-surgical infections, it is reasonable to think that the longer the time elapsed since the prosthesis placement, the more complex and mature the biofilm will be, and therefore the less likely attempts at DAIR are to succeed. Indeed, several studies have shown a higher risk of failure associated with the age of the prosthesis^{20,40,44,47}. The cut-off for considering a poor prognosis has been

suggested to be one month after the prosthesis placement^{22,47}, but a limit of three months is probably more suitable^{15,20,33,42}.

The value of prescribing antibiotics with high activity against biofilm-embedded bacteria has been well established in staphylococcal infections treated with rifampin plus fluoroquinolones^{37,45,48} and also in infections caused by Gram-negative bacilli (GNB) treated with ciprofloxacin^{35,39,42}. The usefulness of administering these treatments in the context of streptococcal and enterococcal infections is uncertain^{49,50}. In some etiologies (for instance, fungal infections), authors have argued against attempting DAIR^{51,52}.

RECOMMENDATIONS

1. The best candidates for attempting eradication treatment with implant retention are those who:
 - a) Have an early post-surgical (up to three months after the placement of the prosthesis) or haematogenous infection (A-II), with a stable implant, and surrounding skin and soft tissues in good condition.
 - b) Have a short duration of symptoms (≤ 3 weeks) (B-II).
- c) Can be treated with rifampin (staphylococcal infections) or fluoroquinolones (infections caused by GNB) (A-II).
2. Some patients who do not strictly meet the above criteria may still benefit from this strategy, but its implementation should be considered on an individualized basis, since there is a higher likelihood of failure (B-II).

In what cases of PJI should a strategy including the removal of the prosthesis be offered? What results are to be expected?

The removal of the prosthesis facilitates the control and eradication of the infection: The elimination of foreign bodies and necrotic tissue enhances antibiotic activity. However, prosthesis removal also requires various complex surgical procedures which may deplete bone stock and reduce joint function. The removal of the implant should be considered as an eradication strategy in the setting of chronic infections, in cases of prosthetic loosening, when the surrounding skin and soft tissue are in poor condition, and when no antibiotics with good activity against biofilm-embedded bacteria are available.

The 2-step exchange procedure, which was first described in 1983⁵³, is the classic treatment of choice for chronic PJI, and it is still frequently applied at most centers. In the first step, the prosthesis and all foreign material (including the bone cement) are removed, and an exhaustive debridement of all non-viable tissues is performed, as well as synovectomy, generous irrigation of the surgical site, reaming of the medullary canal, and the placement of a cement spacer which locally elutes antibiotics. Then, systemic antimicrobials are prescribed for a certain period of time. Once the antibiotic therapy is finished, and if the infection is considered cured, the second step (prosthesis re-implantation) is performed. The rate of failure in hip prosthesis after re-implantation is 0-10%, and slightly higher (5-15%) in studies with 5-10 years of follow up^{5,18,54-57}. In the case of knee prosthesis, the rates of failure range are from 0-18% when follow up is short, and from 9-34% if it is longer⁵⁸⁻⁶¹. The 2-step exchange procedure is also the

commonest surgical management in cases in which DAIR has been attempted but has failed, as well as in acute PJI when a DAIR strategy is unsuitable.

In the context of a 2-step exchange procedure, antibiotics were traditionally administered intravenously for six weeks, in accordance with the recommendations of the American school. However, the role of systemic antimicrobial therapy in this setting and its choice, route, and duration are controversial, as well as the indication for rifampin in infections caused by Gram-positive microorganisms. The best moment for performing the 2nd-step surgery is not well defined, nor is the need for monitoring the values of C-reactive protein (CRP) in order to take this decision. Other areas of uncertainty include the choice of the antimicrobial prophylaxis for the new implant, the need to obtain samples for microbiology during the 2ndstep, and the question of how these cultures should be interpreted.

In recent years, the performance of a 1-step exchange procedure has emerged as an attractive possibility, especially in infected hip prosthesis. This practice consists in removing the implant and, in the same surgical procedure, re-implanting a new prosthesis (Table 4)⁶²⁻⁸⁶. The technique is half way between DAIR (also a single surgical procedure, but offering a more thorough eradication of the infection) and the 2-step exchange procedure, in which the prosthesis is implanted with a higher guarantee of sterility in the surgical site. The 1-step exchange procedure may be considered in non-immunosuppressed patients with a chronic PJI, with surrounding soft tissues in good condition, with sufficient bone stock, and if the infection is caused by low-virulent microorganisms susceptible to antimicrobials with activity against sessile (biofilm-embedded) bacteria. This strategy may also be considered in some cases of acute PJI in which the removal of the prosthesis and later re-implantation is not excessively complex.

Finally, the removal of the prosthesis without further placement of a new implant is another option, which may be considered in patients for whom re-implantation is not viable due to the anatomy of the joint, the patient's baseline condition or his/her functional ability. In Girdlestone's resection arthroplasty, the femoral diaphysis is fitted in the acetabulum⁸⁷. The knee arthrodesis may be performed by external fixation⁸⁸ or by intramedullary nailing⁸⁹. In highly complex surgical scenarios, or in patients with a short life expectancy, the placement of a permanent cement spacer may be considered⁹⁰. Lastly, in some exceptional cases amputation may be necessary.

RECOMMENDATIONS

1. The prosthesis should be removed in cases of chronic PJI (A-II).
2. A 2-step exchange procedure is recommended in patients with chronic PJI (A-II).
3. In patients with acute PJI who are not candidates for eradication treatment with implant retention, a 2-step exchange procedure is recommended (B-II).
4. The performance of a 1-step exchange procedure may be considered in non-immunosuppressed patients if they have good bone stock, if the prosthetic surrounding soft tissues are in good condition, and if the infection is caused by microorganisms susceptible to antibiotics with good activity against sessile (biofilm-embedded) bacteria (B-II).
5. In patients with acute PJI in whom the removal of the prosthesis is not very complex, a 1-step exchange procedure is recommended as long as the causative

microorganisms are susceptible to antibiotics with good activity against biofilm-embedded bacteria (C-III).

In what cases of PJI should implant retention without attempted eradication be considered? What results should be expected?

SAT is seen as an alternative strategy for cases of PJI in which the surgical treatment cannot be performed or will be insufficient for eradicating the infection. SAT consists in the indefinite administration of antibiotics; the goal is not to eradicate the infection but to alleviate the symptoms and to prevent (or slow down) the progression of the infection. This situation should be distinguished from cases in which it is considered that prolonging antimicrobial therapy will actually eradicate the infection.

In the two case series which reported the proportion of patients with PJI treated with this strategy, SAT was an infrequent therapeutic option (5-8%)^{91,92}. However, it may be chosen in up to 36.5% of patients over the age of 80 years⁹³. SAT may be considered in patients with acute PJI in whom DAIR has failed and salvage prosthesis removal has been ruled out, or in chronic PJI if no prosthesis removal is to be performed, for any of the following reasons: the functional results are expected to be unsatisfactory; the risks or potential consequences after surgery are disproportionate to the present symptoms; the patient presents another condition that argues against or delays the surgery; life expectancy is short; there is a major surgical contraindication, or the patient refuses to undergo surgery.

The use of SAT may also be considered in situations in which the likelihood of failure after surgical and medical therapy is very high. Possible examples are: 1) chronic PJI with partial exchange of the prosthetic components (nevertheless, good results have recently been reported after the exchange of only the femoral stem in selected cases, with no need for SAT)⁹⁴; 2) acute PJI managed with DAIR and a high likelihood of failure (and/or severe potential consequences if failure actually occurs); i.e., immunosuppressed patients or patients undergoing chemotherapy, or debridement performed by arthroscopy and/or without exchange of removable components, or use of suboptimal antimicrobial therapy. Alternatively, these patients could be followed up closely, reserving the possibility of starting SAT at any moment if signs of relapse are observed.

The following conditions need to be met for the indication of SAT:

- a) Identification of the microorganism causing the infection.
- b) Availability of oral antibiotics which are not toxic when administered over long periods of time. The use of SAT with parenteral antibiotics with long half-life has been reported, but this strategy is very rarely applied⁹⁵.
- c) Possibility of a close follow-up of the patient.

In addition, it should be considered that pain due to looseness or implant instability will be not reverted by SAT.

It is difficult to determine the effectiveness of SAT, although an idea can be obtained by indirect means. In a cohort of cases with PJI managed with DAIR and prolonged antimicrobial therapy for more than one year, the rate of failure among

patients stopping treatment was 4-fold higher than those who continued²⁰. Although the majority of patients who stopped antibiotics did not fail (meaning that the infection was actually eradicated), the occurrence of failure in some of them indicated that a proportion of those who were not cured by a DAIR strategy did in fact benefit from antimicrobial therapy and thus avoided or delayed failure, which mainly occurred within the first four months of antibiotic withdrawal. Another more recent retrospective cohort study has shown that SAT achieved better results than avoiding long-term antibiotics in a group of patients with high risk of failure after DAIR or after a 2-step exchange procedure (68.5% vs. 41.1%)⁹⁶. The reasons for prescribing SAT in that study are not clear, but it adds evidence regarding the usefulness of SAT. In addition, the experience of SAT as salvage therapy in cases of failure in some patients treated with other strategies^{38,93,97}, and the occurrence of failure after stopping SAT³¹, argue in favour of its use.

The efficacy of SAT is uncertain, because of the difficulties in performing research in this particular area. No controlled trials have been performed, observational studies include patients with acute PJI in whom the use of SAT may not be necessary, and there are certain differences in the definition of endpoints between studies. Indeed, while some authors consider SAT to be successful if surgery is finally avoided (even if surgical samples yield no microorganisms)^{91,98}, others also require the relief of symptoms as a criterion of success^{20,92,97,99}. With this heterogeneity, success rates range between 23% and 84%. Series showing the best results included patients with early infections^{20,92,99}, many of whom probably did not need SAT. In the study published by Marculescu *et al*³¹, the 2-year rate of success was 53% (95%CI: 42-64%) when considering only the 78 patients who were actually followed during the period. By contrast, in the works by Segreti⁹² and Byren²⁰, after excluding early infection, the outcome was favourable in 75% and 68% of cases (with 4 and 2 years of follow-up respectively). Few authors have analysed the parameters predicting failure of SAT, but it seems that the presence of a sinus tract and infection caused by *S. aureus* carry a worse prognosis^{31,99}.

Bearing all these considerations in mind, and also the implications of long-term antimicrobial therapy, the indication for SAT must be carefully weighed up. The use of SAT in patients with early PJI managed with prosthesis retention should be avoided if no clear factors for failure are present. In the same way the temptation to use this strategy and thus avoid the need for complex but potentially eradicated surgery should be resisted.

RECOMMENDATIONS

1. Treatment with SAT may be considered in situations in which medical and surgical strategies are unlikely to cure the patient, and non-toxic long-term antimicrobials are available (B-II).
2. Treatment with SAT is not indicated in acute PJI managed early, with appropriate debridement and optimized antimicrobial therapy (E-II).

Attempted eradication without implant removal

When should eradication with prosthesis retention be attempted, and what surgical technique should be used?

The importance of performing the debridement as soon as possible has already been stressed. The quality of the debridement is a key point in this strategy. Ideally, the patient must be stable from a hemodynamic, respiratory and metabolic point of view, so that s(he) is in the best possible condition to undergo surgery. In addition, the debridement should be performed by an expert surgical team^{15,25,100}. If possible, antibiotics should be withheld until the time of surgery to ensure that the samples taken yield representative microorganisms; the presence of severe sepsis or septic shock is an exception.

Surgical debridement must be performed by open arthrotomy¹⁰¹. The evidence available discourages the use of arthroscopy in this setting, because the debridement it obtains is of poorer quality and does not permit the exchange of removable components. The results appear to be far worse when the debridement is performed by arthroscopy than when it is performed by open arthrotomy^{20,102}. Nonetheless, some series including very selected patients have showed that arthroscopy could be considered as initial surgical treatment^{103,104}.

In the first phase of debridement (the “dirty” part of the procedure), cleaning must be very aggressive and methodical. Correct visualization is required, therefore the need for a wide surgical approach using the previous incision. All infected and necrotic tissues must be extensively debrided, as well as the synovial tissue. The loosening of the components of the prosthesis must be ruled out¹⁰¹.

The importance of the exchange of the removable components of the prosthesis and its final impact in the outcome are controversial. The availability of spare parts is sometimes a matter of concern. Nevertheless, there are strong arguments in favour of this practice: the exchange of removable components allows the debridement of spaces of the joint which are difficult to reach, it facilitates the cleaning of the hidden surface of these components (*undersurface*), and it obtains a more effective detachment of the bacterial biofilm. In addition, the removed components may be sonicated, thus increasing the efficiency of the microbiological diagnosis. Finally, some recent studies have proven that exchanging the removable components of the prosthesis improves prognosis^{44,105}.

Experience learnt in traumatological surgery of open wounds¹⁰⁶⁻¹⁰⁸ indicates that debridement must be followed by generous irrigation of the joint, but there is no consensus regarding the precise technique^{109,110}. With the evidence available, the recommendation is to irrigate a large volume of saline (at least 9 L) using a low-pressure system^{101,106,107,111,112}. There is no evidence supporting the use of antiseptics or local antibiotics during the surgical cleaning.

After debridement and irrigation, the “clean” phase of the procedure begins. The surgical field and surgical instruments must be replaced with new sterile materials. The surgical team must change their gloves and gowns, and antiseptics must be re-applied in the surgical field.

RECOMMENDATIONS

1. Surgical debridement must be performed promptly by an expert surgical team, with the patient in the best possible condition (C-III).

2. The surgical approach must be performed by open arthrotomy. Arthroscopy should only be considered in selected cases, and performed by expert surgeons (A-II).
3. The surgical debridement must be aggressive, methodical and exhaustive.
 - a) If feasible, the removable components of the prosthesis should be exchanged (B-II).
 - b) Copious irrigation (≥ 9 L of saline) is recommended with no additives, performed by a low-pressure system (C-III).

What empirical and definitive antimicrobial treatment is recommended?

Prior considerations regarding planktonic and sessile bacteria in the setting of PJI, and their importance in antimicrobial therapy

Foreign-body infections are characterized by the presence of sessile (biofilm-embedded) bacteria in a stationary phase of growth. However, it is also important to consider planktonic bacteria (in a logarithmic phase of growth) in these infections, especially when they are acute. Actually, most failures observed in the setting of an acute PJI managed with implant retention occur within the first days or weeks after surgical debridement^{25,34,35,40,42,44}. Consistent with these results, several studies have shown a worse prognosis for episodes of PJI with a high inflammatory load (fever, high C-reactive protein, bacteraemia, high leukocyte count), as well as for those needing a second debridement^{25,35,40,43,49}.

Therefore, prioritizing a treatment which focuses only on slow-growing sessile bacteria is debatable, at least in the first days or weeks after debridement. Specifically, rifampin may have an antagonistic effect on β -lactams and other antimicrobials with good activity against rapidly-growing bacteria, and may thus reduce their efficacy¹¹³⁻¹¹⁵. In addition, the use of rifampin or fluoroquinolones in a context of high bacterial inoculum increases the odds of resistance and may undermine these valuable antibiotics at a later stage in the treatment, when their anti-biofilm activity is crucial¹¹⁶.

In summary, surgical debridement is an important element in the efforts to reduce the bacterial inoculum. An optimized initial antibiotic treatment with good activity against rapidly-growing planktonic bacteria should be provided, ideally based on intravenous β -lactams, lipopeptides, or glycopeptides administered for at least 7 days. Once the most inflammatory component of the infection and the initial bacterial inoculum have been reduced, the treatment can focus on the biofilm-embedded bacteria. Table 5 summarizes the recommendations for the treatment of patients managed with implant retention.

RECOMMENDATIONS

1. After surgical debridement, antibiotics with good activity against rapidly-growing planktonic bacteria should be provided, ideally based on β -lactams, lipopeptides, or glycopeptides (B-III).
2. This initial treatment must be administered intravenously for at least 7 days before switching to an optimized antimicrobial therapy focused on the treatment of biofilm-embedded bacteria (C-III).

Staphylococcal infections

The most important microorganism in this context is *Staphylococcus aureus*. Coagulase-negative staphylococci (CNS) are less frequent (but not rare); their treatment is based on the extrapolation of the results of clinical and experimental studies of *S. aureus*.

The fundamental initial treatment (during the logarithmic phase of growth) for methicillin-susceptible *S. aureus* (MSSA) is cloxacillin (cefazolin is an alternative, offering similar efficacy), although its activity is suboptimal when there is a high bacterial inoculum. The addition of daptomycin may provide synergy, as shown by *in vitro* studies and animal experimental models, and it possesses good activity against biofilm-embedded bacteria¹¹⁷. Given the difficulties of this scenario this combination may be considered, but at present no clinical experience is available.

For methicillin-resistant *S. aureus* (MRSA), vancomycin has been the standard of treatment, but its bactericidal ability and the clinical results obtained are unsatisfactory¹¹⁸. *In vitro* studies and experimental animal models have shown daptomycin to be more bactericidal¹¹⁹⁻¹²². If daptomycin is to be used, high doses (8-10 mg/kg/d) and a combination with a second drug are recommended in order to increase the efficacy and to avoid the emergence of resistant subpopulations¹²³⁻¹²⁵. Combinations of daptomycin with cloxacillin or with fosfomycin have been shown to be synergistic and effective in experimental animal models of MRSA foreign-body infection, but there is no clinical experience¹²⁶. Although there are no clinical comparative data, the authors of these guidelines favour the use of daptomycin plus cloxacillin as the initial treatment for PJI by methicillin-resistant strains.

Rifampin has excellent activity against staphylococcal biofilms, but it should not be administered alone due to the high risk of resistance development during therapy^{127,128}. Rifampin-based combinations are the treatment of choice against slow-growing biofilm-embedded bacteria, ideally in combination with fluoroquinolones^{15,37,43-45,103,129,130}. Levofloxacin is intrinsically more active than ciprofloxacin and is less likely to develop resistance^{131,132}. Moxifloxacin is less frequently used: although its intrinsic anti-staphylococcal activity is higher¹³³, experimental models have failed to prove a higher efficacy¹³⁴. In addition, rifampin induces the metabolism of moxifloxacin, therefore limiting the usefulness of this combination¹³⁵.

When fluoroquinolones cannot be used, the best alternative rifampin-based combination remains uncertain. Daptomycin plus rifampin is an attractive alternative based on experimental studies and a limited clinical experience^{129,136-138}. The combination of fosfomycin and rifampin showed similar efficacy in an animal experimental model¹³⁹. Other options with rifampin (or oral sequential treatments following the above combinations) include the addition of linezolid¹⁴⁰, fusidic acid^{33,141}, co-trimoxazole^{142,143}, or clindamycin¹⁴⁴. There is also limited experience with combinations of rifampin and minocycline⁹⁷. The clinical relevance of the ability of rifampin to induce the metabolism of the other antibiotics is not well known¹⁴⁵⁻¹⁴⁷. The choice of one or other treatment should be individualized after taking account of the potential adverse events, the drug-to-drug interactions, and the advantages of oral over intravenous administration.

In some instances, it will not be possible to use rifampin (because of toxicity, drug-to-drug interactions, or resistant strains). In these cases, the best treatment is not well defined at present. The combinations of daptomycin with fosfomycin¹³⁹, with linezolid¹⁴⁸, with co-trimoxazole^{149,150}, or with levofloxacin¹⁵¹ have shown good activity in *in vitro* studies and experimental animal models. Monotherapy with a

fluoroquinolone, co-trimoxazole, or linezolid, or other combinations of antimicrobials may be an alternative^{114,133,152,153}. There is also some experience with the combination of fusidic acid and antimicrobials other than rifampin^{154,155}.

RECOMMENDATIONS

1. Initial treatment (antibiotics against planktonic bacteria):
 - a) Methicillin-susceptible strains: cloxacillin (or cefazolin) (B-II), or cloxacillin + daptomycin (C-III).
 - b) Methicillin-resistant strains: daptomycin + cloxacillin, or daptomycin + fosfomycin (C-III), or vancomycin (B-II).
2. Subsequent treatment (against biofilm-embedded bacteria):
 - a) Treatment of choice: rifampin + levofloxacin (A-II).
 - b) If fluoroquinolones cannot be used: combinations of rifampin with co-trimoxazol (B-II), linezolid (B-II), clindamycin (B-II), fusidic acid (B-II), or daptomycin (B-III).
 - c) If rifampin cannot be used: combinations of daptomycin with fosfomycin (B-III), cloxacillin (B-III), linezolid (B-III), co-trimoxazol (C-III), or levofloxacin (C-III); or combinations of 2 oral antibiotics or monotherapy with levofloxacin (B-III), or moxifloxacin (B-III), co-trimoxazol (BIII), or linezolid (B-III).

Streptococcal infections

The recommended therapy for streptococcal PJI is based on β -lactams (ceftriaxone or penicillin), both for the initial phase of treatment and later for sessile microorganisms^{12,15}. Although β -lactams are known to have poor activity against biofilm-embedded bacteria, this may be less important in infections which are believed to have a better prognosis. However, the actual experience is scarce and heterogeneous, with a wide range of cure rates (42-94%)^{27,29,156-158}. Some authors have suggested that patients treated with fluoroquinolones or rifampin-based combinations may have a better prognosis, especially in infections caused by virulent streptococci^{159,160}.

RECOMMENDATIONS

1. For initial treatment (planktonic phase): penicillin or ceftriaxone (B-II).
2. Subsequent treatment (biofilm-embedded bacteria): penicillin or ceftriaxone (B-II), followed by amoxicillin (B-II), either in combination with rifampin or not (B-III); alternatively, levofloxacin (B-III) either in combination with rifampin or not (B-III), or monotherapy with clindamycin or linezolid in the case of allergy to fluoroquinolones (C-III).

Infections caused by Enterococcus faecalis

Ampicillin is the treatment of choice^{12,15}. The addition of aminoglycosides has been questioned: they have not shown any advantage in clinical studies, and they may increase the risk of ototoxicity and nephrotoxicity¹⁶¹. By contrast, there is some clinical experience supporting the use of rifampin⁵⁰ or the addition of ceftriaxone or ceftaxime^{162,163}. As alternatives, vancomycin¹⁶¹, teicoplanin¹⁶⁴⁻¹⁶⁶, or linezolid^{167,168} may be used.

RECOMMENDATIONS

1. The treatment of choice is ampicillin, followed by oral amoxicillin (B-II).
2. It can be administered in combination with ceftriaxone (B-III) or rifampin (B-III).
3. Teicoplanin or linezolid are possible alternatives (C-III).

Infections caused by GNB

A β -lactam with activity against the specific GNB is indicated during the initial phase of treatment (planktonic bacteria): a 3rd-generation cephalosporin for *Enterobacteriaceae*, or ertapenem for extended-spectrum β -lactamase (ESBL)- producing or AmpC β -lactamase-producing GNB, or an anti-pseudomonal β -lactam for *Pseudomonas aeruginosa*.

For the subsequent treatment of biofilm-embedded bacteria, the possibility to administer fluoroquinolones (ciprofloxacin) is decisive, because this treatment significantly improves the prognosis of these infections and is therefore the treatment of choice in all cases of PJI caused by GNB^{34,35,39,42,169}. For infections caused by *P. aeruginosa*, it is reasonable to administer two antibiotics, including a β -lactam and a fluoroquinolone¹⁶⁹.

If there is resistance to fluoroquinolones, the prognosis of the infection relies on β -lactams, which may be insufficient in this phase of slow-growing biofilm-embedded bacteria. In this regard, and bearing in mind that fluoroquinolones resistance is an increasing problem, more studies evaluating the efficacy of alternative antibiotic regimes are needed. The combination of colistin with β -lactams may be an option, given its activity on biofilm-embedded bacteria in specific targets within the biofilm structure which are different and complementary to those of other antibiotics¹⁷⁰⁻¹⁷². Colistin also increases the permeability of the bacterial membrane, thus facilitating the activity of other antimicrobials^{173,174}. Several experimental and clinical studies have demonstrated higher activity in colistin-based combinations than in monotherapies¹⁷⁵⁻¹⁷⁷. Still, more studies supporting the use of colistin are required; its potential disadvantages (complex pharmacokinetics, uncertain dosage, intravenous route, and significant risk for nephrotoxicity) need to be considered.

Fosfomycin combined with β -lactams may also be an alternative, given its synergistic effect, its activity against biofilm-embedded bacteria¹⁷⁵ and its good bone diffusion¹⁷⁸, but there is no clinical experience with this treatment. Tigecycline may be considered as part of a combination in the salvage treatment of infections caused by multi-drug resistant microorganisms¹⁷⁹. Finally, co-trimoxazole is considered as a minor antibiotic compared with fluoroquinolones, but it may have a role in prolonging therapy via the oral route.

RECOMMENDATIONS

1. For initial treatment (planktonic phase): a β -lactam (a 3rd-generation cephalosporin for *Enterobacteriaceae*, a carbapenem for ESBL or AmpC β -lactamase producing GNB, and an anti-pseudomonal β -lactam for *P. aeruginosa*) (B-III).
2. Subsequent treatment (biofilm-embedded bacteria):
 - a) Treatment of choice: a fluoroquinolone (ciprofloxacin) (A-II).
 - b) If fluoroquinolones cannot be used (due to resistance, toxicity...): continue treatment with a β -lactam (B-III) combined or not with colistin (B-III) or fosfomycin (C-III), or monotherapy with co-trimoxazole (C-III).

Culture-negative PJI

A microbiological isolate may be absent in 5-9% of cases of PJI, especially if patients have received antibiotics prior to sampling^{38,180-182}. The performance of clinical and experimental studies in this scenario is difficult by definition, and the best antimicrobial regime has not been defined. In spite of the uncertainty and the challenge they represent, these infections do not carry a worse prognosis even if no antibiotics with activity against multi-drug resistant microorganisms are used¹⁸⁰. In this situation, it seems reasonable to administer antimicrobials with activity against the most frequent microorganisms (i.e., staphylococci, streptococci, and GNB)¹⁷⁹. The inclusion of MRSA in the antimicrobial spectrum of the regime chosen depends on the clinical context of the patient. It also seems logical to keep the antibiotic spectrum as similar as possible to the one the patient was receiving before sampling, given that it may have interfered with the culture results.

RECOMMENDATIONS

1. If possible, the use of antibiotics prior to a valid sampling (i.e., joint aspirate, and/or intraoperative cultures) should be avoided (B-III).
2. The antimicrobial treatment must be active against the most prevalent microorganisms. The need for antibiotic activity against multi-drug resistant microorganisms must be considered in accordance with the patient's clinical and epidemiological context (C-III).
3. If antibiotics have been administered prior to the sampling and they are considered as potentially responsible for the absence of microbiological diagnosis, the antimicrobial spectrum of this treatment should be considered when choosing the new antibiotic regime (C-III).

What is the optimal duration of the antimicrobial treatment?

The initial antimicrobial treatment, which is intended to reduce the planktonic component of the infection, should be based on β -lactams, glycopeptides or lipopeptides administered intravenously for at least seven days. Then, the oral route may be used as long as antibiotics with high bioavailability are prescribed, such as levofloxacin, rifampin, co-trimoxazole, linezolid, or clindamycin. Otherwise, it will be necessary to prolong intravenous administration of the drug.

A long treatment was empirically recommended for PJI cases managed with implant retention, ranging from 3 to 6 months¹⁵. However, long treatments increase the risk of adverse events, have an impact on the patient's microbiota and environment, and have a higher economic cost¹⁸³⁻¹⁸⁶. Several retrospective studies have suggested a similar rate of success for shorter treatments^{32,35,40,43,187}, and a recent multicenter randomized clinical trial showed that an 8-week course of levofloxacin plus rifampin was as effective as 3-6 months in acute staphylococcal PJI¹⁸⁸.

The value of CRP as an acute phase reactant and for follow-up is relative. Persistently high values of CRP after the first weeks of debridement may suggest persistence of the infection, but many patients present abnormally high values of CRP

for a long time. Thus, the normalization of CRP is not a criterion for extending the antimicrobial therapy beyond the recommended duration^{179,189}.

RECOMMENDATIONS

1. For acute staphylococcal PJI managed with rifampin and levofloxacin, an 8-week schedule of treatment after debridement appears sufficient for most patients (B-I).
2. For PJI caused by other microorganisms treated with antibiotics with good activity against biofilm-embedded bacteria (i.e., ciprofloxacin for PJI caused by GNB, 8 weeks is also a reasonable duration) (B-III).
3. In other clinical scenarios, the most appropriate duration of treatment remains uncertain. A variable period between 8 and 12 weeks may be adequate (B-III).
4. Monitoring of CRP during the follow-up is advisable; the persistence of high values is suggestive of treatment failure (B-III), but its total normalization must not be a condition for deciding the end of therapy (B-II).

How should patients be followed up and for how long?

During the antibiotic treatment (8-12 weeks) a close follow up performed by an expert in antimicrobial therapy is recommended, in order to guarantee observance and to monitor potential toxicity, drug interactions, and other adverse events of the treatment. Failure after surgical debridement usually occurs within the first 6 months, and is rare after 1 year of follow-up^{20,23,28,37,43,130,190}. Overall, it is reasonable to follow the patients closely during the antimicrobial treatment and during the first weeks after withdrawal of antibiotics. The frequency of visits may then decrease progressively during the first year, and become annual, or once every two years, after the first 2 years of follow up.

RECOMMENDATIONS

1. During antimicrobial therapy, a close follow up of observance and potential adverse events of the treatment is recommended, performed by a clinician with expertise in antibiotics (C-III).
2. During the first 6 months after the end of a treatment aiming at eradication, patients must be followed up closely (B-III).
3. The frequency of follow-up visits may decrease afterwards. Follow-up should last at least one year (B-III).

Attempted eradication with prosthesis removal and a 2-step exchange procedure

What is the role of systemic antimicrobial treatment? What is the most appropriate length and route?

The management with a 2-step exchange procedure is complemented by antimicrobial treatment, the goal being to provide high concentrations of antibiotics at the site of infection. This may be achieved by administering systemic antibiotics, or using cement spacers loaded with antibiotics and placed at the surgical site, or with the combination of the two, which is the most common strategy. A study including 68 cases of hip PJI proved the use of combined antimicrobial therapy (local and systemic) to be superior to systemic antibiotics alone¹⁹¹. Systemic antibiotics have classically been administered

intravenously over a period of 6 weeks between the first and second surgical step. Nevertheless, recent studies have questioned the value of such long treatments if antibiotic-loaded cement spacers are used (as long as the local antimicrobials are active against the microorganism isolated in the first-step surgery)¹⁹²⁻¹⁹⁸.

The possibility of only providing local antibiotics is limited by the reduced availability of antimicrobials for loading the cement spacers (not all can be used), and by potential risks such as superinfection by other microorganisms (indeed, the cement spacer is a new foreign-body in the surgical site), or the selection of difficult-to-treat phenotypical variants of bacteria (i.e., staphylococcal small colony variants)¹⁹⁹. As a consequence, at present there is not enough evidence to abandon the prescription of systemic antibiotics, although shortening the length in the setting of PJI caused by low-virulent microorganisms (i.e., CNS) might be considered. For the management with a 2-step exchange procedure of PJI caused by more virulent microorganisms, and/or suppurative and inflammatory infections (i.e., PJI caused by *S. aureus*) administration of a prolonged treatment is reasonable.

Systemic antibiotics are begun after the first-step surgery. If the etiology has been identified during the pre-surgical evaluation, a targeted antibiotic may be used. Otherwise, wide-spectrum antimicrobial therapy is recommended while waiting for the microbiological results after the first-step surgery. In the case of chronic PJI caused by CNS, a lower rate of positive cultures during the second-step surgery (re-implantation) has been observed when anti-staphylococcal antibiotics with a *universal* spectrum have been administered (i.e., glycopeptides, daptomycin, or linezolid)^{200,201}.

While the American school has classically recommended that the intravenous route be maintained throughout the treatment, in the recent IDSA guidelines and the international recommendations on PJI there is a consensus on administering part of the antibiotics orally (as long as the antimicrobial has a good bioavailability), after a short intravenous schedule of 7-14 days^{12,21}. Some studies also support this practice²⁰²⁻²⁰⁶.

The isolation of microorganisms in samples taken during the second-step surgery is interpreted in a similar way to the “positive intraoperative cultures” category in Tsukayama’s classification (Table 2). Most authors have prescribed 4 to 6 weeks of antibiotics in order to avoid the contamination of the new implant^{200,201,207}. However, little evidence is available on the usefulness of this treatment, or on the most appropriate duration.

RECOMMENDATIONS

1. The two-step exchange procedure should include a targeted intravenous antimicrobial treatment for 4 to 6 weeks (A-II), or 1-2 weeks of intravenous antibiotics followed by oral antimicrobials with good bioavailability for a total duration of 6 weeks (B-II).
2. In chronic PJI caused by CNS, “universal” anti-staphylococcal antimicrobial therapy (i.e., glycopeptides, daptomycin, or linezolid) may be considered after the first-step surgery (prosthesis removal), because this carries a lower rate of positive cultures during the second-step surgery (re-implantation) (C-III).
3. Shortening the systemic antimicrobial treatment could be considered for cases of PJI due to low-virulent microorganisms, such as CNS or *Propionibacterium acnes*, as long as the first-step surgery has included a thorough and exhaustive debridement of the

joint, and a cement spacer loaded with antibiotics active against the microorganism responsible for the infection has been used (B-II).

4. When samples taken during the second-step surgery yield a microorganism, a new 4-6 weeks course of antibiotics is recommended (B-II).

Is rifampin necessary in staphylococcal infections managed with a 2-step exchange procedure?

Rifampin is one of the most active antibiotics against slow-growing biofilm-embedded bacteria. In addition, the combination of rifampin with fluoroquinolones decreases the likelihood of the emergence of resistance to both antibiotics¹³¹. However, the usefulness of rifampin has not been proven in the setting of a 2-step exchange procedure^{12,16}.

In most case series reporting the efficacy of a 2-step exchange procedure, rifampin was not included in the antimicrobial treatment and cure rates were near 90%. Therefore, there is not enough evidence to evaluate this antibiotic in this scenario. Theoretically, the complete removal of the prosthesis and a thorough surgical debridement would be able to eradicate all the biofilm (in both the prosthesis and periprosthetic bone), and the role of rifampin would be less relevant. Nevertheless, rifampin may still be of benefit in cases in which the surgery was not optimal and where fragments of cement and osteitic bone may remain. Likewise, in cases presenting a significant inflammatory load or those caused by *S. aureus*, it is reasonable to administer a rifampin-based combination, as long as the microorganism is susceptible and there are no toxicity or drug-to-drug interactions. In these cases, there is no reason for delaying the administration of rifampin after surgery, since in the majority of cases the bacterial inoculum will not be high and there will be no bacteremia.

RECOMMENDATIONS

1. At present, it is not clear whether rifampin should be administered to treat staphylococcal infection managed with a two-step exchange procedure.
 - a) The indication of rifampin in a chronic non-inflammatory infection should be based on the thoroughness of the surgical debridement (C-III).
 - b) Rifampin is recommended in cases with a significant inflammatory presentation, especially those caused by *S. aureus* (C-III).

What is the role of local antimicrobial treatment (cement spacers)? Which kind should be used?

During the first-step surgery, once the prosthetic material and foreign bodies have been removed and the joint and bone debrided, an acrylic cement spacer loaded with antibiotics (ALS) is put in place. The main goals of the ALS are: to occlude the hollow space left after the prosthesis removal; to stabilize the joint; to maintain joint mobility as much as possible before the second-step surgery is performed, as well as the limb function; and to avoid muscle contracture and joint shortening²⁰⁸. The spacers may be static or dynamic, and both types achieve similar eradication rates²¹.

The role of the local antibiotic provided via ALS in eradicating infection is not well defined. Theoretically, its activity depends on the eluted concentration of the antibiotic,

which should be higher than the microorganism's MIC over a sufficient period of time^{198,209-213}. Aminoglycosides (gentamicin and less frequently tobramycin) were the antibiotics initially added to ALS, and so they have been the most frequently used^{214,215}. Later, other antimicrobials such as clindamycin or erythromycin were added in order to include Gram-positive microorganisms in the antimicrobial spectrum²¹⁶⁻²¹⁸.

The elution of antibiotics from the cement is maximal (≥ 30 mg/L) during the first 48 hours. Later, it decreases progressively over the next 15-30 days^{213,219}. *In vitro* data suggest that the concentrations achieved are sufficient to avoid neo-formation of biofilm on a sterile surface, but not to eradicate a pre-formed biofilm on that surface²²⁰.

The selection of resistant microorganisms has been observed on the surface of gentamicin-loaded cement spacers or cement beads^{201,221,222}. This phenomenon is predominant in CNS, but it has also been observed in GNB. The combination of vancomycin and gentamicin in the spacer, which was introduced a decade ago²²³, offers theoretical advantages over aminoglycosides alone because of the vancomycin-gentamicin synergy against Gram-positive microorganisms. The combination also includes a wider antimicrobial spectrum, thus offering protection against the development of resistant microorganisms which may be responsible for superinfection during the second-step surgery^{201,222}. There is very little information comparing the results of these two options (monotherapy vs. combination in ALS). A retrospective study including 146 patients who underwent a 2-step exchange procedure and the placement of an ALS (83 with gentamicin alone and 63 with vancomycin-gentamicin) showed a lower rate of positive cultures during the second-step surgery in the combination group (2.8% vs. 13.4%)²²⁴. In our opinion, while waiting for more comparative studies specifically addressing this question, it is reasonable to use vancomycin-gentamicin loaded spacers, for the reasons outlined above. The recent publication by the International Consensus on Prosthetic Joint Infection supports the use of a spacer combining vancomycin and gentamicin or tobramycin for most infections²¹.

Spacers may be industrially pre-formed or created manually during the surgery. In pre-formed spacers, the antibiotic is homogeneously distributed; the biomechanical characteristics comply with the ISO rules, but only the following antimicrobials are available: gentamicin, clindamycin plus gentamicin, and vancomycin plus gentamicin. By contrast, manually-made spacers allow an individualized design and choice of the antibiotic to be used according to the microorganism causing the infection and its antibiotic susceptibility profile, the patient's renal function and his/her allergies or intolerances¹⁹⁸. No studies to date have evaluated the ideal dosage of antibiotics to be mixed with the cement so that it is effective but does not perturb the resistance of the cement. However, an amount of antibiotic equivalent to 1-10% of the cement weight is accepted (vancomycin 0,5-4 g or gentamicin 0,25-4.8 g per 40 g of acrylic cement)²¹. The risk of nephrotoxicity after a two-step exchange procedure has been highlighted in a recent review²²⁵. Nevertheless, the authors acknowledge the limitations of the published studies for attributing the responsibility for the adverse event to the antibiotics absorbed, and stress the need for well-designed prospective studies.

Not all antibiotics can be mixed with acrylic cement. The characteristics required are thermostability (heat may inactivate some antimicrobials, such as echinocandins), hydrosolubility (non-hydrosoluble antimicrobials have poor elution), a high, progressive,

and maintained elution, and hypoallergenicity.^{198,226} The antibiotics used in acrylic cements are shown in Table 6.

Some controversy exists regarding the use of ALS in PJI caused by multi-drug resistant microorganisms. Some authors have stressed that the spacer behaves as a foreign body, thus facilitating the persistence of the infection, and recommend a two-step exchange procedure without the ALS^{15,199}. Nevertheless, the use of the ALS may be still considered, as long as it is loaded with an antimicrobial active against these multi-drug resistant microorganisms²²⁷.

RECOMMENDATIONS

1. Antibiotic-loaded spacers are recommended in the two-step exchange procedure (B-II).
2. The dose of local antibiotic ranges between 0,5 and 4 g of vancomycin, and 0,25 and 4.8 g of gentamicin or tobramycin (per every 40 g of acrylic cement) (C-III).
3. The use of combined local antibiotics (vancomycin-gentamicin) is recommended until further evidence specifically addressing this topic is available (C-III).
4. In PJI caused by multi-drug resistant microorganisms, spacers may be still used as long as they are loaded with antibiotics active against these microorganisms (C-III).

When is the best time to perform the second-surgical step?

The final goal of a 2-step exchange procedure is the placement of a definitive prosthesis in a sterile surgical site. No randomized controlled trials have been performed to establish the best moment for re-implantation. In old cohort studies, re-implantation within the first three weeks after prosthesis removal was associated with a higher rate of failure²²⁸. Some European cohort studies have shown good results performing re-implantation within 2 to 6 weeks after prosthesis removal, as long as the infection was caused by microorganisms other than MRSA, enterococci, or multi-drug resistant GNB¹⁵.

Currently, the most widely accepted strategy is to perform the re-implantation after 4 to 6 weeks of antimicrobial therapy plus an antibiotic-free period of 2 to 8 weeks²²⁹⁻²³². An excessive period of time (>6 months) between prosthesis removal and re-implantation may have a negative impact on the functional prognosis of the new prosthesis²⁰⁹.

The absence of symptoms during and after the antimicrobial therapy is not diagnostic of eradication of the infection, but most experts consider that an antibiotic-free period increases the safety margin of infection control and also on the efficacy of the antimicrobial treatment. In addition, an antibiotic-free period before the second-step surgery may help to restore the patient's skin microbiota and reduce the risk of superinfection of the new prosthesis. In the absence of more scientific evidence, a period of 2 to 8 weeks between the end of therapy and the placement of a new prosthesis has been classically used^{59,233}.

The optimal time for placing the new prosthesis is chosen according to clinical local signs, laboratory tests, intraoperative inspection, and the histopathological study at the time of re-implantation. The IDSA guidelines recommend assessing erythrocyte sedimentation rate (ESR) and CRP in order to evaluate the success of treatment before reimplantation¹². Both these parameters have traditionally been monitored, along with

the improvement of clinical signs²³⁴. However, several recent studies have observed that the CRP and ESR values before the second-step surgery are not helpful for predicting the persistence of the infection²³⁵⁻²³⁷. This is why some authors argue against delaying second-step surgery even in the presence of high values of these parameters¹⁹⁸. Nevertheless, notable changes in these markers not attributable to other reasons may indicate the persistence of the infection or a superinfection. Therefore, ESR and CRP values, the possible need for an extra debridement before the second-step surgery, and the best time for re-implantation must be interpreted in the context of the entire clinical scenario²³⁵⁻²³⁷.

Analysis and culture of the synovial fluid obtained from a joint aspirate before re-implantation have been proposed by some authors in some doubtful cases²³⁶⁻²³⁹. However, as discussed below, this culture has a low sensitivity for predicting persistence of the infection²³⁹. More highly-powered studies are needed in order to evaluate the value of new markers and techniques, including the role of molecular biology procedures in this context²⁴⁰.

RECOMMENDATIONS

1. In the two-step exchange procedure, an antibiotic-free period of 2 to 8 weeks and clinical stability before the second-step surgery is recommended (C-III).
2. The monitoring of ESR and/or CRP is recommended. The persistence of values above the normal range does not necessarily indicate the persistence of the infection, and re-implantation should not be delayed (B-II). However, significant changes in these serum markers may imply the persistence of the infection or a superinfection (C-III).

Is it necessary to take new samples for microbiological analysis before and/or during the second-step surgery? How should the results be interpreted?

The two-step exchange procedure does not totally guarantee a sterile surgical site during prosthesis replacement. Therefore, sampling at this time is a common procedure in order to certify the eradication of the initial infection and the absence of superinfection. The sampling is usually performed during the second-step surgery, after a minimal antibiotic-free period of 2 weeks^{238,239,241-243}. Overall, studies have shown good sensitivity for finding microorganisms, ranging between 10 and 25%. The microorganisms isolated in the second-step surgery are usually resistant to the antibiotics locally used in the spacer, and also to those administered systemically²⁰⁰.

The isolation of CNS during the second-step surgery, which usually occurs in infections originally also caused by CNS, is even more difficult to interpret (i.e., whether it represents contamination or infection) and to define whether they imply a new infection or the persistence of the previous infection. Some genotypic studies highlight the difficulty of this analysis compared with other studies which are only based on the phenotypical features of CNS and cannot assess the possibility of a polyclonal infection^{76,200,201,238,244,245}. As already mentioned, the frequency of microorganisms during the second-step surgery is lower if the anti-staphylococcal therapy administered after the prosthesis removal is “universal” (glycopeptides, daptomycin, or linezolid)^{200,201}.

In spite of the clinical implications of the presence of microorganisms in the second-step surgery, there is no solid evidence regarding the interpretation of this phenomenon and its management. Generally, the criteria defined by Atkins *et al* for the microbiological diagnosis of chronic PJI are applied²⁴⁶.

Murillo *et al* reviewed their experience with positive cultures taken during second-step surgery. Patients with positive cultures received supplementary antibiotics for a mean of 30 days and did not present relapse during follow-up²⁰⁰. Likewise, Bejon *et al* observed that patients with positive intraoperative cultures from samples taken during re-implantation and treated with antibiotics for a prolonged time did not have worse prognosis than the group with negative cultures²³³. Therefore, in the case of diagnosis of a persistent infection or a superinfection, a targeted antimicrobial during a period of 4 to 6 weeks appears reasonable.

The presence of a cement spacer between the first and second-step surgery has been associated with the possibility of perpetuating the infection, since it is a foreign body^{221,247}. Some studies advocate performing cultures of this material in order to rule out the persistence of infection. Nelson *et al* showed that 50% of patients with a positive culture of the sonicated cement spacer presented subsequent infection relapse, as compared with only 11% of cases with a negative culture.²⁴⁸ Similar results were observed by Sorli *et al*²⁰⁷ Other authors argue that the result of the culture of the spacer should be evaluated as an additional sample along with the ensemble of samples taken during the second-step surgery, and so Atkins' criteria should be applied to the whole of samples (tissues and spacer)²⁰¹. More studies are required to evaluate the culture of the spacer or the liquid obtained after its sonication.

In a retrospective study, a group of patients undergoing systematic sampling before re-implantation were compared with another group without systematic sampling. In the first group, 9% of cases had positive pre-surgical cultures; these patients again underwent debridement, cement spacer exchange and a new course of antibiotics before re-implantation, after which there was only one case of infection relapse (3%). By contrast, the second group managed with no sampling before re-implantation presented an infection recurrence rate of 14%²³⁸.

Nevertheless, there is no consensus on the usefulness of sampling the joint aspirate before the second-step surgery; the sensitivity of this practice is low, so its systematic performance is not recommended¹⁹⁸. Nonetheless, bearing in mind the specificity of a positive result, it could be useful in cases with a clinical and analytical suspicion of poor prognosis (persistent local signs of inflammation, persistently high biological markers) or in cases of difficult treatment (i.e., multi-drug resistant GNB or fungi).

RECOMMENDATIONS

1. Sampling of tissues and the cement spacer during the second-step surgery of a two-step exchange procedure is recommended in order to guarantee the sterility of the surgical site where the new prosthesis is to be placed (B-II).
2. Culture of the joint aspirate before the second-step surgery is not systematically recommended, although it may be of some use when the clinical and analytical evaluation of the patient suggests poor evolution, or in difficult-to-treat episodes caused by multi-drug resistant microorganisms or fungi (C-II).

3. Cultures of samples taken during the second-step surgery may be considered as positive if ≥ 1 or ≥ 2 of them yield a microorganism, depending on its pathogenicity (C-III).

What is the best prophylaxis for the second-step surgery and how long should it be prescribed?

Antimicrobial prophylaxis must be administered in this setting (actually, it is indicated for any surgery with placement of orthopedic hardware)²⁴⁹, but guidelines do not specify the type or the length.

Only two studies have addressed the issue of antimicrobial prophylaxis for the second-step surgery in the setting of a two-step exchange procedure. In a case-control study of patients with knee prosthesis, 28 patients were administered oral *prolonged prophylaxis* for 28-43 days using various antibiotics (67% co-trimoxazole, 14% linezolid) while 38 were given a *standard prophylaxis*. Whether or not this prophylaxis was targeted and took in consideration the initial etiology of the infection was not specified. Notable differences were observed after one year of follow up: the rate of reinfection was only 1/28 (4%) in cases treated with prolonged oral prophylaxis, but 6/38 (15.8%) in the controls²⁵⁰.

In another retrospective study, the effect of prolonged vs. standard prophylaxis was evaluated in chronic hip PJI managed with a 2-step exchange procedure. None of the 22 patients receiving *prolonged prophylaxis* presented relapse, compared with six out of 44 patients who received *standard prophylaxis*. In four of these, the etiology was the same as the one that caused the original infection. These results were compared with a control group of patients undergoing prosthesis revision for aseptic reasons, in which only two out of 410 patients developed infection²⁵¹.

In addition, in three supplementary studies^{238,252,253} the microorganism causing infection after the second-step surgery was identical to the original etiology in 18/19, 8/9, and 2/11 cases respectively, thus supporting the idea that antimicrobial prophylaxis should target the initial etiology of the infection. Moreover the isolation of CNS from samples obtained during the second step is not a rare event^{200,201,248}, and good results have been obtained when these isolates are treated (in the case they are interpreted as significant)^{200,233,235}. For this reason, the use of a glyco-lipopeptide from the second step until cultures are known (pre-emptive treatment) seems reasonable.

Nevertheless, superinfection by a different microorganism is an alternative cause of failure when exchanging the prosthesis^{201,248,254}. These microorganisms are probably part of the patient's skin microbiota, which is likely to have been modified by previous antimicrobial pressure and by the nosocomial environment. All these factors support the use of wide-spectrum antimicrobials for prophylaxis during the second-step surgery. Tandel and Patel's review acknowledges as common practice the use of antimicrobial prophylaxis in the second step until cultures are negative¹⁸².

RECOMMENDATIONS

1. Wide-spectrum antibiotic prophylaxis including nosocomial microorganisms that may potentially cause superinfection of the new prosthesis is recommended for the second-step surgery of a 2-step exchange procedure (C-III).

2. “Preemptive treatment” including microorganisms that could be isolated during the second-step surgery (usually multi-drug resistant SNC) is recommended: vancomycin (or another glycopeptide or lipopeptide) during the first 5 days after re-implantation or until confirmation that the samples taken during the second-step surgery yield no microorganisms (C-III).

Attempted eradication with prosthesis removal and a 1-step exchange procedure

What is the antimicrobial treatment for patients undergoing a 1-step exchange procedure?

There is no consensus on the best antimicrobial treatment for patients undergoing a 1-step exchange procedure, since no randomized or comparative studies have been carried out in this setting. Our evaluation of the literature includes 28 studies (Table 4), but few specify the antibiotic therapy or report the use of various treatment regimens; therefore, no recommendations are forthcoming^{62-84,86,255,256}. In spite of this heterogeneity, the cure rates reported were higher than 80%, suggesting that the efficacy of this strategy depends mostly on the surgeon’s ability to perform an exhaustive debridement and removal of all foreign bodies and necrotic tissues.

In the majority of reports, antimicrobial treatment begins at the time of prosthesis removal. However, some authors start antibiotics some time (one week to several months) before the surgical procedure^{81,83,86}, in order to reduce the bacterial load and lower the risk of contamination of the new prosthesis. This seems reasonable, especially in cases with a highly inflammatory clinical presentation or those caused by pathogenic and virulent microorganisms such as *S. aureus* or GNB. In these cases, active antibiotics administered for 3 to 5 days prior to the procedure may be sufficient. It is very important to establish the microbiological diagnosis of the infection before-hand in order to be able to target the antibiotic therapy.

If there is no microbiological diagnosis at the time of the procedure, wide-spectrum antibiotic therapy should be initiated after the sampling and maintained until the results of these cultures are available. This empirical antimicrobial therapy should include a glycopeptide (vancomycin or teicoplanin), daptomycin, or linezolid, in combination with a β -lactam with anti-pseudomonal activity (ceftazidime or cefepime, or else meropenem in patients colonized or with previous infections by ESBL-producing *Enterobacteriaceae*, or in those presenting with risk factors for infection by these microorganisms). Once the etiology is known, a tailored specific antimicrobial treatment may be administered, following the same criteria as in the management of PJI with implant retention (Table 5).

Regardless of the decision regarding the time to start antibiotics, it is crucial to meet the fundamental principles of antimicrobial prophylaxis for the new prosthesis and to include a high antimicrobial concentration at the surgical site throughout the procedure²⁵⁷. Two studies have suggested that the administration of antibiotics prior to intraoperative sampling does not reduce the sensitivity of the cultures^{258,259}, but this is still a matter of controversy. The recommendation is to delay the infusion of antibiotics until the samples have been taken. This issue is less important if the etiological diagnosis

is already available and a targeted antimicrobial therapy has been decided in the days prior to the procedure.

As mentioned above, high antibiotic concentrations must be achieved at the surgical site throughout the procedure. Therefore, the antibiotic dose must be repeated if the operation lasts for more than twice the antibiotic's half-life or if the blood loss is greater than 1.5 L²⁶⁰.

RECOMMENDATIONS

1. Beginning an antimicrobial therapy 3 to 5 days prior to the 1-step exchange procedure is recommended if the etiological diagnosis has already been made, especially in infections caused by *S. aureus* or GNB (C-II).
2. Regardless of the decision regarding when to start antibiotics, an appropriate antimicrobial prophylaxis throughout the procedure must be guaranteed (A-I).
3. If no antimicrobial therapy has been initiated before the procedure, it should be delayed until the intraoperative sampling has been performed (C-III).

How long should antimicrobial treatment last?

A tailored antimicrobial therapy should be administered once the results of the cultures taken during surgery are available, the goal being to complete the treatment of peri-prosthetic osteomyelitis that may still persist after the prosthesis exchange. The authors with the most experience with 1-step exchange procedure²⁶¹ report a cure rate of 80% after following a protocol that only includes 10-14 days of intravenous antibiotics, usually without rifampin. These results may be due to the performance of a thorough debridement and the use of cement loaded with antibiotics during the procedure. In contrast, in the setting of staphylococcal infections the IDSA guidelines recommend intravenous antibiotics for a period of 2 to 6 weeks, then switching to a rifampin-based combination for a total of 3 months of antimicrobial therapy¹².

The overall success of this medical and surgical strategy depends not only on the surgeon's ability to thoroughly eradicate the lifeless tissues and the inert material, but also on the administration of an appropriate antimicrobial therapy that prevents the new prosthesis from being colonized. The total length of therapy (including intravenous and oral antibiotics) reported in the literature varies widely, from 10 days to 6 months (Table 4). These studies do not take into consideration the degree of inflammation that finally leads to the prosthesis exchange or the etiology of the infection. The 1-step exchange procedure strategy is halfway between DAIR (indicated in acute cases of infection, with a high degree of inflammation and usually caused by virulent microorganisms) and the 2-step exchange procedure (chronic or subacute PJI, rarely suppurative, and caused by less virulent microorganisms). Thus, it seems reasonable that the length of therapy in this scenario will vary according to these parameters.

RECOMMENDATION

1. A minimum of 7 days of intravenous antibiotics with activity against the microorganisms causing the infection is recommended (dosage summarized in Table 5), followed by oral antibiotics for a total of 4-8 weeks (B-II).

What is the role of the local antimicrobial treatment (cement)?

There are no comparative studies evaluating the efficacy of mixing antibiotics with cement during 1-step exchange procedure. In our review of the literature (Table 4), we found five studies reporting 237 patients who underwent prosthesis exchange with no local antibiotics, with a cure rate ranging between 83 and 100%, while there were 22 papers including 1,704 cases in which cement with antibiotics was used, with cure rates between 72-100%. The data reported in the literature support the practice of 1-step exchange procedure with non-cemented prosthesis, thus with no possibility of using local antibiotics. Still, in these cases bone allograft or calcium sulfate beads may be used as carriers of local antibiotics⁸². It is the surgeon who decides whether the prosthesis should be cemented or non-cemented. If a cemented prosthesis is selected, the usual antibiotics are gentamicin, tobramycin, and vancomycin. The accumulated experience suggests that these local antibiotics are safe, have minimal toxicity, and do not disrupt the cement's consistency in the long term.

RECOMMENDATION

1. If it has been decided to use a cemented prosthesis, a local antibiotic with activity against the microorganism causing the infection is recommended. If the etiology is unknown at the moment of the exchange procedure, the combination of vancomycin plus gentamicin is recommended (C-III).

What is the treatment for the 'positive intraoperative cultures' (PIOC) category of Tsukayama's classification?

The PIOC category described by Tsukayama (Table 2) includes patients submitted to a 1-step exchange procedure due to the loosening of a prosthesis which was assumed to be non-infectious, but in which the samples taken during surgery finally yielded microorganisms. Actually, these patients are very similar to those with a chronic PJI undergoing a 1-step exchange procedure; however, they have very subtle or non-existent symptoms, and so do not receive antimicrobials except for the standard surgical antibiotic prophylaxis.

The interpretation of these cultures and the management of this scenario are quite controversial, and reconsideration of the whole clinical picture and complementary data is needed: pre-surgical CRP and ESR, patient's age and condition, data on synovial fluid, histological information, and so on. In some cases these cultures are just read as contaminants, especially if there is one single positive culture²⁶², and in other cases the surgical debridement and irrigation are considered to be sufficient treatment. Nevertheless, some patients have later developed an infection of the new prosthesis, caused by the microorganisms isolated during the previous prosthesis exchange (PIOC)²⁶³.

In spite of the absence of contrasted evidence in this setting, when the cultures are considered to be significant most authors support the use of antibiotics during 4-6 weeks and see no need for additional surgery. Broadly speaking, they follow the same

principles as for PJI managed with a 1-step exchange procedure. The outcome after an antimicrobial therapy is satisfactory in most cases^{22,264}.

RECOMMENDATION

1. In the case of PIOC (Tsukayama's classification) an antimicrobial treatment of 4 to 6 weeks is recommended. There is no need for further surgery. The same protocol is followed as in cases of PJI managed with a 1-step exchange procedure (B-III).

What is the treatment for cases in which no new prosthesis is to be inserted after the removal of the infected one?

The difficulty of treatment is significantly reduced when the infected prosthesis is not to be replaced. The same antibiotics and dosages used in DAIR (Table 5) may help the choice of the antimicrobial treatment, but the length of treatment may be shortened to 4-6 weeks, depending on the clinical follow-up.

RECOMMENDATION

1. For cases in which the infected prosthesis is not to be replaced after its removal, the same antibiotics as those used for DAIR may be administered (Table 5) (B-II).
2. In these cases, the length of therapy may be shortened to 4 to 6 weeks (C-III).

Implant retention and long-term suppressive antibiotics (SAT) without attempted eradication

Is it necessary to perform a surgical debridement before initiating SAT?

It is reasonable to think that reducing the bacterial inoculum and debriding the infected tissues may favour the success of SAT. Indeed, in most series of PJI managed with SAT, patients underwent surgical debridement. However, in many of these cases the decision to initiate SAT may well have been taken after performing the debridement. The difficult decision to starting SAT is considered in clinically stable patients, with few symptoms, and especially if the surgical risk is high. Indeed, in a case series of elderly patients with PJI managed with SAT, only 24% underwent surgery⁹³. Another important advantage of performing surgical debridement is the possibility of obtaining valuable samples for culture. Access to reliable cultures in this setting is particularly important, since the samples taken from sinus tracts are not really representative. If the patient cannot undergo surgical debridement, obtaining a valid sample via joint aspirate or synovial biopsy should be considered.

RECOMMENDATIONS

1. A surgical debridement before beginning SAT is recommended, if feasible (C-III).
2. Obtaining a valid sample for culture before starting SAT is particularly important (C-III).

What are the most appropriate antibiotics for SAT? Are combinations of antimicrobials convenient or necessary? What is the role for rifampin?

In published case series, the most frequently reported antibiotics are the combination of minocycline plus rifampin or β -lactams alone^{91-93,99}. Other less frequently antibiotics used are co-trimoxazole, clindamycin, and fluoroquinolones. It is difficult to draw recommendations from the literature regarding the usefulness of these antibiotics for SAT.

RECOMMENDATIONS

1. For the choice of the specific antibiotic for SAT, the antimicrobial susceptibility of the microorganism causing the infection, the safety of the drug and the observance of the treatment must be considered. Except for the initial stages of SAT, these aspects must prevail over the optimization of the antimicrobial treatment (C-III).
2. Except for some particular cases, the use of combinations (and therefore the use of rifampin) is not recommended (D-III).

Is it necessary to administer intravenous antibiotics at the beginning of SAT?

In most published series, patients were initially treated with intravenous antibiotics for several weeks. This was very likely done in the setting of the standard protocol of PJI management at each center, and not necessarily as a consequence of choosing a SAT strategy. In addition to the surgical debridement, an initial intravenous antimicrobial treatment may contribute to reducing the bacterial inoculum, thus favouring good evolution. Nevertheless, it seems unlikely that prolonged intravenous treatment is really relevant for the success or failure of SAT, since its efficacy is based on its indefinite administration.

RECOMMENDATION

1. In cases undergoing surgical debridement, an initial intravenous treatment for at least 7 days is recommended. Nevertheless, prolonged intravenous treatment is not necessary when deciding on SAT management (C-III).

Is it possible to have defined periods with no antimicrobial treatment?

Antibiotic-free periods are not reported in any of the series undergoing with SAT. Some of these studies report the occurrence of failure after antibiotic withdrawal, usually within the first 4 months after discontinuation²⁰.

RECOMMENDATIONS

1. If it is necessary to stop or change the antibiotics due to the occurrence of adverse events, long periods without antibiotics are not recommended (D-III).

Is SAT safe? What about its effect on the microbiota?

Safety issues in the setting of antimicrobial therapy scheduled for long periods (like SAT) are of paramount importance. Although information is very scarce, the safety data published for case series of SAT indicate a low rate of antibiotic withdrawal due to adverse events^{31,92,99}. However, caution is required when interpreting these results: the rate of antibiotic withdrawal within the first weeks or months of treatment may have been underestimated, since patients who discontinued treatment early were probably removed from the series.

Nevertheless, information on the safety of prolonged antimicrobial therapies can be obtained not only from SAT in the setting of PJI or other bone and joint infections, but from other clinical scenarios as well, such as antibiotic prophylaxis in immunosuppressed hosts, infections requiring long treatments (multi-drug resistant tuberculosis, actinomycosis, endocarditis caused by *Coxiella*...), or diseases that also need long antibiotic therapies due to a natural history in which bacterial infection and colonization have a significant role (chronic obstructive pulmonary disease, cystic fibrosis, acne, and so on).

The analysis of the diversity of protocols, patients, and antibiotics is overwhelmingly complex. Table 7 summarizes the most interesting information for the management of PJI for each antibiotic separately.

RECOMMENDATIONS

1. The prescription and control of a SAT must be performed by an expert in antimicrobial therapy, who will periodically follow up the clinical evolution of the infection and assess the possible occurrence of adverse events (B-III).
2. The use of linezolid is discouraged in SAT due to high risk of toxicity, which limits its prolonged administration (E-I).
3. The use of β -lactams, or low doses of co-trimoxazole, is recommended. Alternatively, other antimicrobials such as minocycline or clindamycin may be administered (C-III).

Acknowledgments

We thank Michael Maudsley for reviewing the English version, and Juan Manuel García-Lechuz for his critical review of the document.

J.L-T holds a clinical research contract "Sara Borrell" (CD14/00176) from the Instituto de Salud Carlos III, Spanish Ministry of Economy and Competitiveness.

Supported by Plan Nacional de I+D+i and Instituto de Salud Carlos III, Subdirección General de Redes y Centros de Investigación Cooperativa, Ministerio de Economía y Competitividad, Spanish Network for Research in Infectious Diseases (REIPI RD12/0015) - co-financed by European Development Regional Fund "A way to achieve Europe" ERDF.

Conflict of interests

JA has served as speaker for and has received fees for advisory boards from Pfizer and Novartis.

JC has served as speaker for Astellas, AstraZeneca, MSD, Novartis and Angelini, and has received fees for advisory boards from Astellas, Pfizer, AstraZeneca and MSD.

JE has received fees for lectures from Laboratorios Leti and support for attending conferences from Pfizer, bioMérieux, Alere, Laboratorios Leti and Novartis

JPH has served as speaker for MSD, Astellas, Novartis, Pfizer, and Astra Zeneca and also has received fees for advisory boards from MSD, Astellas, Novartis, Pfizer, Angelini, Basilea and Astra Zeneca

CP has received fees from Pfizer, MSD, Astellas, Novartis, Zambon, Salvat, and Mefasa-pharma

DRP has received lecture fees, travel support for attending meetings and fees for advisory boards from Novartis, Astellas, Merck and Pfizer.

AS has received fees as speaker from Pfizer, Novartis, MSD and Astellas.

The rest of the authors declare no conflict of interests.

Appendix 1. Abbreviations

ALS: acrylic cement spacer loaded with antibiotics.

CNS: Coagulase-negative staphylococci.

CRP: C-reactive protein.

DAIR: debridement, antibiotics, implant retention.

ESBL: extended-spectrum β -lactamase.

ESR: erythrocyte sedimentation rate.

GNB: Gram-negative bacilli.

IDSA: Infectious Diseases Society of America.

MSSA: methicillin-susceptible *S. aureus*.

MRSA: methicillin-resistant *S. aureus*.

PIOC: Positive intraoperative cultures.

PJI: prosthetic joint infection(s).

SEIMC: Spanish Society of Clinical Microbiology and Infectious Diseases.

SAT: suppressive antimicrobial therapy.

References

1. Kurtz S, Ong K, Lau E, Mowat F, Halpern M. Projections of primary and revision hip and knee arthroplasty in the United States from 2005 to 2030. *J Bone Joint Surg Am.* 2007 Apr;89(4):780-5.
2. Kurtz SM, Lau E, Watson H, Schmier JK, Parvizi J. Economic burden of periprosthetic joint infection in the United States. *J Arthroplasty.* 2012 Sep;27(8 Suppl):61-5.
3. Garrido-Gómez J, Arrabal-Polo MA, Girón-Prieto MS, Cabello-Salas J, Torres-Barroso J, Parra-Ruiz J. Descriptive analysis of the economic costs of periprosthetic joint infection of the knee for the public health system of Andalusia. *J Arthroplasty.* 2013 Aug;28(7):1057-60.
4. Schwarzkopf R, Oh D, Wright E, Estok DM, Katz JN. Treatment failure among infected periprosthetic patients at a highly specialized revision TKA referral practice. *Open Orthop J.* 2013;7(1):264-71.
5. Berend KR, Lombardi AV, Morris MJ, Bergeson AG, Adams JB, Sneller MA. Two-stage treatment of hip periprosthetic joint infection is associated with a high rate of infection control but high mortality. *Clin Orthop Relat Res.* 2013 Feb;471(2):510-8.
6. Zimmerli W, Ochsner PE. Management of infection associated with prosthetic joints. *Infection.* 2003 Mar;31(2):99-108.
7. Giulieri SG, Graber P, Ochsner PE, Zimmerli W. Management of infection associated with total hip arthroplasty according to a treatment algorithm. *Infection.* 2004 Aug;32(4):222-8.
8. Laffer RR, Graber P, Ochsner PE, Zimmerli W. Outcome of prosthetic knee-associated infection: evaluation of 40 consecutive episodes at a single centre. *Clin Microbiol Infect.* 2006 May;12(5):433-9.
9. Betsch BY, Eggli S, Siebenrock KA, Täuber MG, Mühlemann K. Treatment of joint prosthesis infection in accordance with current recommendations improves outcome. *Clin Infect Dis.* 2008 Apr;46(8):1221-6.
10. Esposito S, Leone S, Bassetti M, Borrè S, Leoncini F, Meani E, et al. Italian guidelines for the diagnosis and infectious disease management of osteomyelitis and prosthetic joint infections in adults. *Infection.* 2009 Dec;37(6):478-96.
11. Société de Pathologie Infectieuse de Langue Française (SPILF), Collège des Universitaires de Maladies Infectieuses et Tropicales (CMIT), Groupe de Pathologie Infectieuse Pédiatrique (GPIP), Société Française d'Anesthésie et de Réanimation (SFAR), Société Française de Chirurgie Orthopédique et Traumatologique (SOFOT), Société Française d'Hygiène Hospitalière (SFHH), et al. Recommendations for bone and

joint prosthetic device infections in clinical practice (prosthesis, implants, osteosynthesis). Société de Pathologie Infectieuse de Langue Française. *Med Mal Infect.* 2010 Apr;40(4):185-211.

12. Osmon DR, Berbari EF, Berendt AR, Lew D, Zimmerli W, Steckelberg JM, et al. Diagnosis and management of prosthetic joint infection: clinical practice guidelines by the Infectious Diseases Society of America. *Clin Infect Dis.* 2013 Jan;56(1):e1-e25.
13. Minassian AM, Osmon DR, Berendt AR. Clinical guidelines in the management of prosthetic joint infection. *J Antimicrob Chemother.* 2014 Sep;69 Suppl 1:i29-35. .
14. Kish MA. Guide to development of practice guidelines. *Clin Infect Dis.* 2001 Mar 15;32(6):851-4.
15. Zimmerli W, Trampuz A, Ochsner PE. Prosthetic-joint infections. *N Engl J Med.* 2004 Oct 14;351(16):1645-54.
16. Cobo J, Del Pozo JL. Prosthetic joint infection: diagnosis and management. *Expert Rev Anti Infect Ther.* 2011 Sep;9(9):787-802.
17. Ziran BH, Rao N, Hall RA. A dedicated team approach enhances outcomes of osteomyelitis treatment. *Clin Orthop Relat Res.* 2003 Sep;(414):31-6.
18. Ibrahim MS, Raja S, Khan MA, Haddad FS. A multidisciplinary team approach to two-stage revision for the infected hip replacement: a minimum five-year follow-up study. *Bone Joint J.* 2014 Oct;96-B(10):1312-8.
19. Bauer S, Bouldouyre M-A, Oufella A, Palmari P, Bakir R, Fabreguettes A, et al. Impact of a multidisciplinary staff meeting on the quality of antibiotherapy prescription for bone and joint infections in orthopedic surgery. *Med Mal Infect.* 2012 Dec;42(12):603-7.
20. Byren I, Bejon P, Atkins BL, Angus B, Masters S, McLardy-Smith P, et al. One hundred and twelve infected arthroplasties treated with «DAIR» (debridement, antibiotics and implant retention): antibiotic duration and outcome. *J Antimicrob Chemother.* 2009 Jun;63(6):1264-71.
21. Parvizi J, Gehrke T, Chen AF. Proceedings of the International Consensus on Periprosthetic Joint Infection. *Bone Joint J.* 2013 Nov;95-B(11):1450-2. Available online at <http://www.msisa-na.org/international-consensus>.
22. Tsukayama DT, Estrada R, Gustilo RB. Infection after total hip arthroplasty. A study of the treatment of one hundred and six infections. *J Bone Joint Surg Am.* 1996 Apr;78(4):512-23.
23. Schoifet SD, Morrey BF. Treatment of infection after total knee

- arthroplasty by débridement with retention of the components. *J Bone Joint Surg.* 1990 Oct;72(9):1383-90.
24. Burger RR, Basch T, Hopson CN. Implant salvage in infected total knee arthroplasty. *Clin Orthop Relat Res.* 1991 Dec;(273):105-12.
 25. Brandt CM, Sistrunk WW, Duffy MC, Hanssen AD, Steckelberg JM, Ilstrup DM, et al. Staphylococcus aureus prosthetic joint infection treated with debridement and prosthesis retention. *Clin Infect Dis.* 1997 May;24(5):914-9.
 26. Tattevin P, Crémieux AC, Pottier P, Hutten D, Carbon C. Prosthetic joint infection: when can prosthesis salvage be considered? *Clin Infect Dis.* 1999 Aug;29(2):292-5.
 27. Meehan AM, Osmon DR, Duffy MCT, Hanssen AD, Keating MR. Outcome of penicillin-susceptible streptococcal prosthetic joint infection treated with debridement and retention of the prosthesis. *Clin Infect Dis.* 2003 Apr 1;36(7):845-9.
 28. Berdal J-E, Skråmm I, Mowinckel P, Gulbrandsen P, Bjørnholt JV. Use of rifampicin and ciprofloxacin combination therapy after surgical debridement in the treatment of early manifestation prosthetic joint infections. *Clin Microbiol Infect.* 2005 Oct;11(10):843-5.
 29. Everts RJ, Chambers ST, Murdoch DR, Rothwell AG, McKie J. Successful antimicrobial therapy and implant retention for streptococcal infection of prosthetic joints. *ANZ J Surg.* 2004 Apr;74(4):210-4.
 30. Barberán J, Aguilar L, Carroquino G, Giménez M-J, Sánchez B, Martínez D, et al. Conservative treatment of staphylococcal prosthetic joint infections in elderly patients. *Am J Med.* 2006 Nov;119(11):993.e7-10.
 31. Marculescu CE, Berbari EF, Hanssen AD, Steckelberg JM, Harmsen SW, Mandrekar JN, et al. Outcome of prosthetic joint infections treated with debridement and retention of components. *Clin Infect Dis.* 2006 Feb 15;42(4):471-8.
 32. Soriano A, García S, Bori G, Almela M, Gallart X, Macule F, et al. Treatment of acute post-surgical infection of joint arthroplasty. *Clin Microbiol Infect.* 2006 Sep;12(9):930-3.
 33. Aboltins CA, Page MA, Buising KL, Jenney AWJ, Daffy JR, Choong PFM, et al. Treatment of staphylococcal prosthetic joint infections with debridement, prosthesis retention and oral rifampicin and fusidic acid. *Clin Microbiol Infect.* 2007 Jun;13(6):586-91.
 34. Hsieh P-H, Lee MS, Hsu K-Y, Chang Y-H, Shih H-N, Ueng SW. Gram-negative prosthetic joint infections: risk factors and outcome of treatment. *Clin Infect Dis.* 2009 Oct 1;49(7):1036-43.

35. Martínez-Pastor JC, Muñoz-Mahamud E, Vílchez F, García-Ramiro S, Bori G, Sierra J, et al. Outcome of acute prosthetic joint infections due to gram-negative bacilli treated with open debridement and retention of the prosthesis. *Antimicrob Agents Chemother*. 2009 Nov;53(11):4772-7.
36. Rodríguez D, Pigrau C, Euba G, Cobo J, García-Lechuz J, Palomino J, et al. Acute haematogenous prosthetic joint infection: prospective evaluation of medical and surgical management. *Clin Microbiol Infect*. 2010 Dec;16(12):1789-95.
37. Senneville E, Joulie D, Legout L, Valette M, Dezèque H, Beltrand E, et al. Outcome and predictors of treatment failure in total hip/knee prosthetic joint infections due to *Staphylococcus aureus*. *Clin Infect Dis*. 2011 Aug;53(4):334-40.
38. Cobo J, Miguel LGS, Euba G, Rodríguez D, García-Lechuz JM, Riera M, et al. Early prosthetic joint infection: outcomes with debridement and implant retention followed by antibiotic therapy. *Clin Microbiol Infect*. 2011 Nov;17(11):1632-7.
39. Aboltins CA, Dowsey MM, Buising KL, Peel TN, Daffy JR, Choong PFM, et al. Gram-negative prosthetic joint infection treated with debridement, prosthesis retention and antibiotic regimens including a fluoroquinolone. *Clin Microbiol Infect*. 2011 Jun;17(6):862-7.
40. Vílchez F, Martínez-Pastor JC, García-Ramiro S, Bori G, Maculé F, Sierra J, et al. Outcome and predictors of treatment failure in early post-surgical prosthetic joint infections due to *Staphylococcus aureus* treated with debridement. *Clin Microbiol Infect*. 2011 Mar;17(3):439-44.
41. Zmistowski B, Fedorka CJ, Sheehan E, Deirmengian G, Austin MS, Parvizi J. Prosthetic joint infection caused by gram-negative organisms. *J Arthroplasty*. 2011 Sep;26(6 Suppl):104-8.
42. Rodríguez-Pardo D, Pigrau C, Lora-Tamayo J, Soriano A, del Toro MD, Cobo J, et al. Gram-negative prosthetic joint infection: outcome of a debridement, antibiotics and implant retention approach. A large multicentre study. *Clin Microbiol Infect*. 2014 Nov;20(11):0911-9.
43. Lora-Tamayo J, Murillo O, Iribarren JA, Soriano A, Sánchez-Somolinos M, Baraia-Etxaburu JM, et al. A large multicenter study of methicillin-susceptible and methicillin-resistant *Staphylococcus aureus* prosthetic joint infections managed with implant retention. *Clin Infect Dis*. 2013 Jan;56(2):182-94.
44. Lora-Tamayo J, Murillo O, Ariza J. Reply to Krause et al. *Clin Infect Dis*. 2013 Jun;56(12):1843-4.
45. Zimmerli W, Widmer AF, Blatter M, Frei R, Ochsner PE. Role of rifampin

for treatment of orthopedic implant-related staphylococcal infections: a randomized controlled trial. Foreign-Body Infection (FBI) Study Group. *JAMA*. 1998 May 20;279(19):1537-41.

46. Sendi P, Banderet F, Graber P, Zimmerli W. Clinical comparison between exogenous and haematogenous periprosthetic joint infections caused by *Staphylococcus aureus*. *Clin Microbiol Infect*. 2011 Jul;17(7):1098-100.
47. Geurts JAP, Janssen DMC, Kessels AGH, Walenkamp GHIM. Good results in postoperative and hematogenous deep infections of 89 stable total hip and knee replacements with retention of prosthesis and local antibiotics. *Acta Orthop*. 2013 Dec;84(6):509-16.
48. Helou El OC, Berbari EF, Lahr BD, Eckel-Passow JE, Razonable RR, Sia IG, et al. Efficacy and safety of rifampin containing regimen for staphylococcal prosthetic joint infections treated with debridement and retention. *Eur J Clin Microbiol Infect Dis*. 2010 Aug;29(8):961-7.
49. Tornero E, Martínez-Pastor JC, Bori G, García-Ramiro S, Morata L, Bosch J, et al. Risk factors for failure in early prosthetic joint infection treated with debridement. Influence of etiology and antibiotic treatment. *J Appl Biomater Funct Mater*. 2014;12(3):129-34.
50. Tornero E, Senneville E, Euba G, Petersdorf S, Rodríguez-Pardo D, Lakatos B, et al. Characteristics of prosthetic joint infections due to *Enterococcus* sp. and predictors of failure: a multi-national study. *Clin Microbiol Infect*. 2014 Nov;20(11):1219-24.
51. Kuiper JWP, van den Bekerom MPJ, van der Stappen J, Nolte PA, Colen S. 2-stage revision recommended for treatment of fungal hip and knee prosthetic joint infections. *Acta Orthop*. 2013 Dec;84(6):517-23.
52. García-Oltra E, García-Ramiro S, Martínez JC, Tibau R, Bori G, Bosch J, et al. [Prosthetic joint infection by *Candida* spp.]. *Rev Esp Quimioter*. 2011 Mar;24(1):37-41.
53. Insall JN, Thompson FM, Brause BD. Two-stage reimplantation for the salvage of infected total knee arthroplasty. *J Bone Joint Surg Am*. 1983 Oct;65(8):1087-98.
54. Lange J, Troelsen A, Thomsen RW, Søballe K. Chronic infections in hip arthroplasties: comparing risk of reinfection following one-stage and two-stage revision: a systematic review and meta-analysis. *Clin Epidemiol*. 2012;4(1):57-73.
55. Puhto A-P, Puhto TM, Niinimäki TT, Leppilahti JI, Syrjälä HPT. Two-stage revision for prosthetic joint infection: outcome and role of reimplantation microbiology in 107 cases. *J Arthroplasty*. 2014 Jun;29(6):1101-4.

56. Schwarzkopf R, Mikhael B, Wright E, Estok DM, Katz JN. Treatment failure among infected periprosthetic total hip arthroplasty patients. *Open Orthop J.* 2014;8(1):118-24.
57. Sánchez-Sotelo J, Berry DJ, Hanssen AD, Cabanela ME. Midterm to long-term followup of staged reimplantation for infected hip arthroplasty. *Clin Orthop Relat Res.* 2009 Jan;467(1):219-24.
58. Jämsen E, Stogiannidis I, Malmivaara A, Pajamäki J, Puolakka T, Konttinen YT. Outcome of prosthesis exchange for infected knee arthroplasty: the effect of treatment approach. *Acta Orthop.* 2009 Feb;80(1):67-77.
59. Mahmud T, Lyons MC, Naudie DD, Macdonald SJ, McCalden RW. Assessing the gold standard: a review of 253 two-stage revisions for infected TKA. *Clin Orthop Relat Res.* 2012 Oct;470(10):2730-6.
60. Pelt CE, Grijalva R, Anderson L, Anderson MB, Erickson J, Peters CL. Two-Stage Revision TKA Is Associated with High Complication and Failure Rates. *Adv Orthop.* 2014;2014(392):659047-7.
61. Masters JPM, Smith NA, Foguet P, Reed M, Parsons H, Sprowson AP. A systematic review of the evidence for single stage and two stage revision of infected knee replacement. *BMC Musculoskelet Disord.* 2013;14(1):222.
62. Tibrewal S, Malagelada F, Jeyaseelan L, Posch F, Scott G. Single-stage revision for the infected total knee replacement: results from a single centre. *Bone Joint J.* 2014 Jun;96-B(6):759-64.
63. Singer J, Merz A, Frommelt L, Fink B. High rate of infection control with one-stage revision of septic knee prostheses excluding MRSA and MRSE. *Clin Orthop Relat Res.* 2012 May;470(5):1461-71.
64. Buechel FF, Femino FP, D'Alessio J. Primary exchange revision arthroplasty for infected total knee replacement: a long-term study. *Am J Orthop.* *Am J Orthop (Belle Mead NJ).* 2004 Apr;33(4):190-8; discussion 198.
65. Foerster von G, Klüber D, Käbler U. [Mid- to long-term results after treatment of 118 cases of periprosthetic infections after knee joint replacement using one-stage exchange surgery]. *Orthopade.* 1991 Jun;20(3):244-52.
66. Jenny J-Y, Lengert R, Diesinger Y, Gaudias J, Boeri C, Kempf J-F. Routine one-stage exchange for chronic infection after total hip replacement. *Int Orthop.* 2014 Dec;38(12):2477-81.
67. Choi H-R, Kwon Y-M, Freiberg AA, Malchau H. Comparison of one-stage revision with antibiotic cement versus two-stage revision results for infected total hip arthroplasty. *J Arthroplasty.* 2013 Sep;28(8

Suppl):66–70.

68. Loty B, Postel M, Evrard J, Matron P, Courpied JP, Kerboull M, et al. [One stage revision of infected total hip replacements with replacement of bone loss by allografts. Study of 90 cases of which 46 used bone allografts]. *Int Orthop*. 1992;16(4):330-8.
69. Sanzén L, Carlsson AS, Josefsson G, Lindberg LT. Revision operations on infected total hip arthroplasties. Two- to nine-year follow-up study. *Clin Orthop Relat Res*. 1988 Apr;(229):165-72.
70. Wroblewski BM. One-stage revision of infected cemented total hip arthroplasty. *Clin Orthop Relat Res*. 1986 Oct;(211):103-7.
71. Buchholz HW, Elson RA, Engelbrecht E, Lodenkämper H, Röttger J, Siegel A. Management of deep infection of total hip replacement. *J Bone Joint Surg Br*. 1981;63-B(3):342-53.
72. Carlsson AS, Josefsson G, Lindberg L. Revision with gentamicin-impregnated cement for deep infections in total hip arthroplasties. *J Bone Joint Surg*. 1978 Dec;60(8):1059-64.
73. Rudelli S, Uip D, Honda E, Lima ALLM. One-stage revision of infected total hip arthroplasty with bone graft. *J Arthroplasty*. 2008 Dec;23(8):1165-77.
74. Mulcahy DM, O'Byrne JM, Fenelon GE. One stage surgical management of deep infection of total hip arthroplasty. *Ir J Med Sci*. 1996 Jan;165(1):17-9.
75. Callaghan JJ, Katz RP, Johnston RC. One-stage revision surgery of the infected hip. A minimum 10-year followup study. *Clin Orthop Relat Res*. 1999 Dec;(369):139-43.
76. Hope PG, Kristinsson KG, Norman P, Elson RA. Deep infection of cemented total hip arthroplasties caused by coagulase-negative staphylococci. *J Bone Joint Surg Br*. 1989 Nov;71(5):851-5.
77. Ure KJ, Amstutz HC, Nasser S, Schmalzried TP. Direct-exchange arthroplasty for the treatment of infection after total hip replacement. An average ten-year follow-up. *J Bone Joint Surg*. 1998 Jul;80(7):961-8.
78. Raut VV, Siney PD, Wroblewski BM. One-stage revision of total hip arthroplasty for deep infection. Long-term followup. *Clin Orthop Relat Res*. 1995 Dec;(321):202-7.
79. Yoo JJ, Kwon YS, Koo K-H, Yoon KS, Kim Y-M, Kim HJ. One-stage cementless revision arthroplasty for infected hip replacements. *Int Orthop*. 2009 Oct;33(5):1195-201.
80. Bori G, Muñoz-Mahamud E, Cuñé J, Gallart X, Fuster D, Soriano A. One-

stage revision arthroplasty using cementless stem for infected hip arthroplasties. *J Arthroplasty*. 2014 May;29(5):1076-81.

81. Winkler H, Stoiber A, Kaudela K, Winter F, Menschik F. One stage uncemented revision of infected total hip replacement using cancellous allograft bone impregnated with antibiotics. *J Bone Joint Surg Br*. 2008 Dec;90(12):1580-4.
82. Winkler H. Bone grafting and one-stage revision of THR - biological reconstruction and effective antimicrobial treatment using antibiotic impregnated allograft bone. *Hip Int*. 2012 Jul;22 Suppl 8(S8):S62-8.
83. Zeller V, Lhotellier L, Marmor S, Leclerc P, Krain A, Graff W, et al. One-stage exchange arthroplasty for chronic periprosthetic hip infection: results of a large prospective cohort study. *J Bone Joint Surg Am*. 2014 Jan 1;96(1):e1.
84. Klouche S, Leonard P, Zeller V, Lhotellier L, Graff W, Leclerc P, et al. Infected total hip arthroplasty revision: one- or two-stage procedure? *Orthop Traumatol Surg Res*. 2012 Apr;98(2):144-50.
85. Sofer D, Regenbrecht B, Pfeil J. [Early results of one-stage septic revision arthroplasties with antibiotic-laden cement. A clinical and statistical analysis]. *Orthopade*. 2005 Jun;34(6):592-602.
86. Drancourt M, Stein A, Argenson JN, Zannier A, Curvale G, Raoult D. Oral rifampin plus ofloxacin for treatment of Staphylococcus-infected orthopedic implants. *Antimicrob Agents Chemother*. 1993 Jun;37(6):1214-8.
87. Castellanos J, Flores X, Llusà M, Chiriboga C, Navarro A. The Girdlestone pseudarthrosis in the treatment of infected hip replacements. *Int Orthop*. 1998;22(3):178-81.
88. Corona PS, Hernández A, Reverté-Vinaixa MM, Amat C, Flores X. Outcome after knee arthrodesis for failed septic total knee replacement using a monolateral external fixator. *J Orthop Surg (Hong Kong)*. 2013 Dec;21(3):275-80.
89. Corona PS, Soldado F, Amat C, Flores X. Two-stage knee arthrodesis using a cemented modular tumour replacement system for recalcitrant septic proximal tibial non-union: a case report. *J Orthop Surg (Hong Kong)*. 2013 Aug;21(2):241-4.
90. Haddad S, Corona PS, Reverté MM, Amat C, Flores X. Antibiotic-impregnated cement spacer as a definitive treatment for post-arthroscopy shoulder destructive osteomyelitis: case report and review of literature. *Strategies Trauma Limb Reconstr*. 2013 Nov;8(3):199-205.
91. Goulet JA, Pellicci PM, Brause BD, Salvati EM. Prolonged suppression of

- infection in total hip arthroplasty. *J Arthroplasty*. 1988;3(2):109-16.
92. Segreti J, Nelson JA, Trenholme GM. Prolonged suppressive antibiotic therapy for infected orthopedic prostheses. *Clin Infect Dis*. 1998 Oct;27(4):711-3.
 93. Prendki V, Zeller V, Passeron D, Desplaces N, Mamoudy P, Stirnemann J, et al. Outcome of patients over 80 years of age on prolonged suppressive antibiotic therapy for at least 6 months for prosthetic joint infection. *Int J Infect Dis*. 2014 Dec 1;29:184-9.
 94. Ekpo TE, Berend KR, Morris MJ, Adams JB, Lombardi AV. Partial Two-stage Exchange for Infected Total Hip Arthroplasty: A Preliminary Report. *Clin Orthop Relat Res*. 2013 Jul 13;472(2):437-48.
 95. Allen J, Adams K, Thompson F, Cullen L, Barlow G. Long-term, once-weekly outpatient teicoplanin use for suppression of chronic prosthetic joint infection. *Int J Antimicrob Agents*. 2013 Feb;41(2):200-1.
 96. Siqueira MBP, Saleh A, Klika AK, O'Rourke C, Schmitt S, Higuera CA, et al. Chronic suppression of periprosthetic joint infections with oral antibiotics increases infection-free survivorship. *J Bone Joint Surg Am*. 2015 Aug 5;97(15):1220-32.
 97. Pavoni GL, Giannella M, Falcone M, Scorzolini L, Liberatore M, Carlesimo B, et al. Conservative medical therapy of prosthetic joint infections: retrospective analysis of an 8-year experience. *Clin Microbiol Infect*. 2004 Sep;10(9):831-7.
 98. Tsukayama DT, Wicklund B, Gustilo RB. Suppressive antibiotic therapy in chronic prosthetic joint infections. *Orthopedics*. 1991 Aug;14(8):841-4.
 99. Rao N, Crossett LS, Sinha RK, Le Frock JL. Long-term suppression of infection in total joint arthroplasty. *Clin Orthop Relat Res*. 2003 Sep;414(414):55-60.
 100. Crockarell JR, Hanssen AD, Osmon DR, Morrey BF. Treatment of infection with débridement and retention of the components following hip arthroplasty. *J Bone Joint Surg*. 1998 Sep;80(9):1306-13.
 101. Haasper C, Buttaro M, Hozack W, Aboltins CA, Borens O, Callaghan JJ, et al. Irrigation and debridement. *J Orthop Res*. 2014 Jan;32 Suppl 1:S130-5 .
 102. Waldman BJ, Hostin E, Mont MA, Hungerford DS. Infected total knee arthroplasty treated by arthroscopic irrigation and débridement. *J Arthroplasty*. 2000 Jun;15(4):430-6.
 103. Dixon P, Parish EN, Cross MJ. Arthroscopic debridement in the

- treatment of the infected total knee replacement. *J Bone Joint Surg Br.* 2004 Jan;86(1):39-42.
104. Chung JY, Ha C-W, Park Y-B, Song Y-J, Yu K-S. Arthroscopic debridement for acutely infected prosthetic knee: any role for infection control and prosthesis salvage? *Arthroscopy.* 2014 May;30(5):599-606.
 105. Choi H-R, Knoch von F, Zurakowski D, Nelson SB, Malchau H. Can implant retention be recommended for treatment of infected TKA? *Clin Orthop Relat Res.* 2011 Apr;469(4):961-9.
 106. Anglen JO. Wound irrigation in musculoskeletal injury. *J Am Acad Orthop Surg.* 2001 Jul;9(4):219-26.
 107. Crowley DJ, Kanakaris NK, Giannoudis PV. Irrigation of the wounds in open fractures. *J Bone Joint Surg Br.* 2007 May;89(5):580-5.
 108. Tejwani NC, Immerman I. Myths and legends in orthopaedic practice: are we all guilty? *Clin Orthop Relat Res.* 2008 Nov;466(11):2861-72.
 109. Conroy BP, Anglen JO, Simpson WA, Christensen G, Phaup G, Yeager R, et al. Comparison of castile soap, benzalkonium chloride, and bacitracin as irrigation solutions for complex contaminated orthopaedic wounds. *J Orthop Trauma.* 1999 Jun;13(5):332-7.
 110. Anglen JO. Comparison of soap and antibiotic solutions for irrigation of lower-limb open fracture wounds. A prospective, randomized study. *Journal of Bone and Joint Surgery.* 2005 Jul;87(7):1415-22.
 111. Owens BD, White DW, Wenke JC. Comparison of irrigation solutions and devices in a contaminated musculoskeletal wound survival model. *J Bone Joint Surg Am.* 2009 Jan;91(1):92-8.
 112. FLOW Investigators, Petrisor B, Sun X, Bhandari M, Guyatt G, Jeray KJ, et al. Fluid lavage of open wounds (FLOW): a multicenter, blinded, factorial pilot trial comparing alternative irrigating solutions and pressures in patients with open fractures. *J Trauma.* 2011 Sep;71(3):596-606.
 113. Hackbarth CJ, Chambers HF, Sande MA. Serum bactericidal activity of rifampin in combination with other antimicrobial agents against *Staphylococcus aureus*. *Antimicrob Agents Chemother.* 1986 Apr;29(4):611-3.
 114. Murillo O, Pachón ME, Euba G, Verdaguer R, Tubau F, Cabellos C, et al. Antagonistic effect of rifampin on the efficacy of high-dose levofloxacin in staphylococcal experimental foreign-body infection. *Antimicrob Agents Chemother.* 2008 Oct;52(10):3681-6 .
 115. Miró JM, García-de-la-Mària C, Armero Y, Soy D, Moreno A, del Río A, et al. Addition of gentamicin or rifampin does not enhance the

- effectiveness of daptomycin in treatment of experimental endocarditis due to methicillin-resistant *Staphylococcus aureus*. *Antimicrob Agents Chemother*. 2009 Oct;53(10):4172-7.
116. Sendi P, Zimmerli W. Antimicrobial treatment concepts for orthopaedic device-related infection. *Clin Microbiol Infect*. 2012 Dec;18(12):1176-84.
 117. Haj El C, Murillo O, Ribera A, Vivas M, García-Somoza D, Tubau F, et al. Comparative efficacies of cloxacillin-daptomycin and the standard cloxacillin-rifampin therapies against an experimental foreign-body infection by methicillin-susceptible *Staphylococcus aureus*. *Antimicrob Agents Chemother*. 2014 Sep;58(9):5576-80.
 118. Bradbury T, Fehring TK, Taunton M, Hanssen A, Azzam K, Parvizi J, et al. The fate of acute methicillin-resistant *Staphylococcus aureus* periprosthetic knee infections treated by open debridement and retention of components. *J Arthroplasty*. 2009 Sep;24(6 Suppl):101-4.
 119. Safdar N, Andes D, Craig WA. In vivo pharmacodynamic activity of daptomycin. *Antimicrob Agents Chemother*. 2004 Jan;48(1):63-8.
 120. Baltch AL, Ritz WJ, Bopp LH, Michelsen P, Smith RP. Activities of daptomycin and comparative antimicrobials, singly and in combination, against extracellular and intracellular *Staphylococcus aureus* and its stable small-colony variant in human monocyte-derived macrophages and in broth. *Antimicrob Agents Chemother*. 2008 May;52(5):1829-33.
 121. Stewart PS, Davison WM, Steenbergen JN. Daptomycin rapidly penetrates a *Staphylococcus epidermidis* biofilm. *Antimicrob Agents Chemother*. 2009 Aug;53(8):3505-7.
 122. Mélard A, García LG, Das D, Rozenberg R, Tulkens PM, Van Bambeke F, et al. Activity of ceftaroline against extracellular (broth) and intracellular (THP-1 monocytes) forms of methicillin-resistant *Staphylococcus aureus*: comparison with vancomycin, linezolid and daptomycin. *J Antimicrob Chemother*. 2013 Mar;68(3):648-58.
 123. Moise PA, North D, Steenbergen JN, Sakoulas G. Susceptibility relationship between vancomycin and daptomycin in *Staphylococcus aureus*: facts and assumptions. *Lancet Infect Dis*. 2009 Oct;9(10):617-24.
 124. Moise PA, Hershberger E, Amodio-Groton MI, Lamp KC. Safety and clinical outcomes when utilizing high-dose (> or =8 mg/kg) daptomycin therapy. *Ann Pharmacother*. 2009 Jul;43(7):1211-9.
 125. Gould IM, Miró JM, Rybak MJ. Daptomycin: the role of high-dose and combination therapy for Gram-positive infections. *Int J Antimicrob Agents*. 2013 Sep;42(3):202-10.

126. Garrigós C, Murillo O, Lora-Tamayo J, Verdaguer R, Tubau F, Cabellos C, et al. Efficacy of daptomycin-cloxacillin combination in experimental foreign-body infection due to methicillin-resistant *Staphylococcus aureus*. *Antimicrob Agents Chemother*. 2012 Jul;56(7):3806-11.
127. Lucet JC, Herrmann M, Rohner P, Auckenthaler R, Waldvogel FA, Lew DP. Treatment of experimental foreign body infection caused by methicillin-resistant *Staphylococcus aureus*. *Antimicrob Agents Chemother*. 1990 Dec;34(12):2312-7.
128. Kadurugamuwa JL, Sin LV, Yu J, Francis KP, Purchio TF, Contag PR. Noninvasive optical imaging method to evaluate postantibiotic effects on biofilm infection in vivo. *Antimicrob Agents Chemother*. 2004 Jun;48(6):2283-7.
129. John A-K, Baldoni D, Haschke M, Rentsch K, Schaerli P, Zimmerli W, et al. Efficacy of daptomycin in implant-associated infection due to methicillin-resistant *Staphylococcus aureus*: importance of combination with rifampin. *Antimicrob Agents Chemother*. 2009 Jul;53(7):2719-24.
130. Ascione T, Pagliano P, Mariconda M, Rotondo R, Balato G, Toro A, et al. Factors related to outcome of early and delayed prosthetic joint infections. *J Infect*. 2015 Jan;70(1):30-6.
131. Kang SL, Rybak MJ, McGrath BJ, Kaatz GW, Seo SM. Pharmacodynamics of levofloxacin, ofloxacin, and ciprofloxacin, alone and in combination with rifampin, against methicillin-susceptible and -resistant *Staphylococcus aureus* in an in vitro infection model. *Antimicrob Agents Chemother*. 1994 Dec;38(12):2702-9.
132. Entenza JM, Vouillamoz J, Glauser MP, Moreillon P. Levofloxacin versus ciprofloxacin, flucloxacillin, or vancomycin for treatment of experimental endocarditis due to methicillin-susceptible or -resistant *Staphylococcus aureus*. *Antimicrob Agents Chemother*. 1997 Aug;41(8):1662-7.
133. San Juan R, García-Reyne A, Caba P, Chaves F, Resines C, Llanos F, et al. Safety and efficacy of moxifloxacin monotherapy for treatment of orthopedic implant-related staphylococcal infections. *Antimicrob Agents Chemother*. 2010 Dec;54(12):5161-6.
134. Murillo O, Pachón ME, Euba G, Verdaguer R, Tubau F, Cabellos C, et al. High doses of levofloxacin vs moxifloxacin against staphylococcal experimental foreign-body infection: the effect of higher MIC-related pharmacokinetic parameters on efficacy. *J Infect*. 2009 Mar;58(3):220-6.
135. Nijland HMJ, Ruslami R, Suroto AJ, Burger DM, Alisjahbana B, van Crevel R, et al. Rifampicin reduces plasma concentrations of moxifloxacin in patients with tuberculosis. *Clin Infect Dis*. 2007 Oct

15;45(8):1001-7.

136. Garrigós C, Murillo O, Euba G, Verdaguer R, Tubau F, Cabellos C, et al. Efficacy of usual and high doses of daptomycin in combination with rifampin versus alternative therapies in experimental foreign-body infection by methicillin-resistant *Staphylococcus aureus*. *Antimicrob Agents Chemother*. 2010 Dec;54(12):5251-6.
137. Saleh-Mghir A, Muller-Serieys C, Dinh A, Massias L, Crémieux A-C. Adjunctive rifampin is crucial to optimizing daptomycin efficacy against rabbit prosthetic joint infection due to methicillin-resistant *Staphylococcus aureus*. *Antimicrob Agents Chemother*. 2011 Oct;55(10):4589-93.
138. Lora-Tamayo J, Parra-Ruiz J, Rodríguez-Pardo D, Barberán J, Ribera A, Tornero E, et al. High doses of daptomycin (10 mg/kg/d) plus rifampin for the treatment of staphylococcal prosthetic joint infection managed with implant retention: a comparative study. *Diagn Microbiol Infect Dis*. 2014 Sep;80(1):66-71.
139. Garrigós C, Murillo O, Lora-Tamayo J, Verdaguer R, Tubau F, Cabellos C, et al. Fosfomicin-daptomycin and other fosfomicin combinations as alternative therapies in experimental foreign-body infection by methicillin-resistant *Staphylococcus aureus*. *Antimicrob Agents Chemother*. 2013 Jan;57(1):606-10.
140. Soriano A, Gómez J, Gómez L, Azanza JR, Pérez R, Romero F, et al. Efficacy and tolerability of prolonged linezolid therapy in the treatment of orthopedic implant infections. *Eur J Clin Microbiol Infect Dis*. 2007 May;26(5):353-6.
141. Peel TN, Buising KL, Dowsey MM, Aboltins CA, Daffy JR, Stanley PA, et al. Outcome of debridement and retention in prosthetic joint infections by methicillin-resistant staphylococci, with special reference to rifampin and fusidic acid combination therapy. *Antimicrob Agents Chemother*. 2013 Jan;57(1):350-5.
142. Euba G, Murillo O, Fernández-Sabé N, Mascaró J, Cabo J, Pérez A, et al. Long-term follow-up trial of oral rifampin-cotrimoxazole combination versus intravenous cloxacillin in treatment of chronic staphylococcal osteomyelitis. *Antimicrob Agents Chemother*. 2009 Jun;53(6):2672-6.
143. Nguyen S, Pasquet A, Legout L, Beltrand E, Dubreuil L, Migaud H, et al. Efficacy and tolerance of rifampicin-linezolid compared with rifampicin-cotrimoxazole combinations in prolonged oral therapy for bone and joint infections. *Clin Microbiol Infect*. 2009 Dec;15(12):1163-9.
144. Czekaj J, Dinh A, Moldovan A, Vaudaux P, Gras G, Hoffmeyer P, et al. Efficacy of a combined oral clindamycin-rifampicin regimen for therapy of staphylococcal osteoarticular infections. *Scand J Infect Dis*.

2011 Dec;43(11-12):962-7.

145. Ribera E, Pou L, Fernández-Solá A, Campos F, López RM, Ocaña I, et al. Rifampin reduces concentrations of trimethoprim and sulfamethoxazole in serum in human immunodeficiency virus-infected patients. *Antimicrob Agents Chemother.* 2001 Nov;45(11):3238-41.
146. Zeller V, Dzeing-Ella A, Kitzis M-D, Ziza J-M, Mamoudy P, Desplaces N. Continuous clindamycin infusion, an innovative approach to treating bone and joint infections. *Antimicrob Agents Chemother.* 2010 Jan;54(1):88-92.
147. Gandelman K, Zhu T, Fahmi OA, Glue P, Lian K, Obach RS, et al. Unexpected effect of rifampin on the pharmacokinetics of linezolid: in silico and in vitro approaches to explain its mechanism. *J Clin Pharmacol.* 2011 Feb;51(2):229-36.
148. Parra-Ruiz J, Bravo-Molina A, Peña-Monje A, Hernández-Quero J. Activity of linezolid and high-dose daptomycin, alone or in combination, in an in vitro model of *Staphylococcus aureus* biofilm. *J Antimicrob Chemother.* 2012 Nov;67(11):2682-5.
149. Avery LM, Steed ME, Woodruff AE, Hasan M, Rybak MJ. Daptomycin-nonsusceptible vancomycin-intermediate staphylococcus aureus vertebral osteomyelitis cases complicated by bacteremia treated with high-dose daptomycin and trimethoprim-sulfamethoxazole. *Antimicrob Agents Chemother.* 2012 Nov;56(11):5990-3.
150. Steed ME, Werth BJ, Ireland CE, Rybak MJ. Evaluation of the novel combination of high-dose daptomycin plus trimethoprim-sulfamethoxazole against daptomycin-nonsusceptible methicillin-resistant *Staphylococcus aureus* using an in vitro pharmacokinetic/pharmacodynamic model of simulated endocardial vegetations. *Antimicrob Agents Chemother.* 2012 Nov;56(11):5709-14.
151. El Haj C, Murillo O, Ribera A, Vivas M, García-Somoza D, Tubau F, et al. Daptomycin combinations as alternative therapies in experimental foreign-body infection caused by methicillin-susceptible *Staphylococcus aureus*. *Int J Antimicrob Agents.* 2015 Aug;46(2):189-95.
152. Stein A, Bataille JF, Drancourt M, Curvale G, Argenson JN, Groulier P, et al. Ambulatory treatment of multidrug-resistant *Staphylococcus*-infected orthopedic implants with high-dose oral co-trimoxazole (trimethoprim-sulfamethoxazole). *Antimicrob Agents Chemother.* 1998 Dec;42(12):3086-91.
153. Morata L, Senneville E, Bernard L, Nguyen S, Buzelé R, Druon J, et al. A retrospective review of the clinical experience of linezolid with or without rifampicin in prosthetic joint infections treated with debridement and implant retention. *Infect Dis Ther.* 2014 Aug 20;3(2):235-43.

154. Atkins B, Gottlieb T. Fusidic acid in bone and joint infections. *Int J Antimicrob Agents*. 1999 Aug;12 Suppl 2:S79-93.
155. Wang J-L, Tang H-J, Hsieh P-H, Chiu F-Y, Chen Y-H, Chang M-C, et al. Fusidic acid for the treatment of bone and joint infections caused by meticillin-resistant *Staphylococcus aureus*. *Int J Antimicrob Agents*. 2012 Aug;40(2):103-7.
156. Duggan JM, Georgiadis G, VanGorp C, Kleshinski J. Group B streptococcal prosthetic joint infections. *J South Orthop Assoc*. 2001;10(4):209-14–discussion 214.
157. Sendi P, Christensson B, Uçkay I, Trampuz A, Achermann Y, Boggian K, et al. Group B streptococcus in prosthetic hip and knee joint-associated infections. *J Hosp Infect*. 2011 Sep;79(1):64-9.
158. Corvec S, Illiaquer M, Touchais S, Boutoille D, van der Mee-Marquet N, Quentin R, et al. Clinical features of group B *Streptococcus* prosthetic joint infections and molecular characterization of isolates. *J Clin Microbiol*. 2011 Jan;49(1):380-2.
159. Fiaux E, Beltrand E, Legout L, Loiez C, Senneville E. Rifampin combination therapy for enterococcal prosthetic joint infection (EPJI). K-240. 51st Internscience Conference on Antimicrobial Agents and Chemotherapy, Sept, 2011. Chicago
160. Lora-Tamayo J, Senneville E, Ribera A, Bernard L, Zeller V, Li H, et al. Streptococcal prosthetic joint infection managed with implant retention. 55st Interscience Conference on Antimicrobi Agents and Chemotherapy. Sept, 2015, San Diego.
161. Helou El OC, Berbari EF, Marculescu CE, Atrouni El WI, Razonable RR, Steckelberg JM, et al. Outcome of enterococcal prosthetic joint infection: is combination systemic therapy superior to monotherapy? *Clin Infect Dis*. 2008 Oct 1;47(7):903-9.
162. Euba G, Lora-Tamayo J, Murillo O, Pedrero S, Cabo J, Verdaguer R, et al. Pilot study of ampicillin-ceftriaxone combination for treatment of orthopedic infections due to *Enterococcus faecalis*. *Antimicrob Agents Chemother*. 2009 Oct;53(10):4305-10.
163. Mainardi JL, Gutmann L, Acar JF, Goldstein FW. Synergistic effect of amoxicillin and cefotaxime against *Enterococcus faecalis*. *Antimicrob Agents Chemother*. 1995 Sep;39(9):1984-7.
164. LeFrock JL, Ristuccia AM, Ristuccia PA, Quenzer RW, Haggerty PG, Allen JE, et al. Teicoplanin in the treatment of bone and joint infections. Teicoplanin Bone and Joint Cooperative Study Group, USA. *Eur J Surg Suppl*. 1992;(567):9-13.
165. Schmit J-L. Efficacy of teicoplanin for enterococcal infections: 63 cases

and review. *Clin Infect Dis*. 1992 Aug;15(2):302-6.

166. Graninger W, Wenisch C, Wiesinger E, Menschik M, Karimi J, Presterl E. Experience with outpatient intravenous teicoplanin therapy for chronic osteomyelitis. *Eur J Clin Microbiol Infect Dis*. 1995 Jul;14(7):643-7.
167. Falagas ME, Siempos II, Papagelopoulos PJ, Vardakas KZ. Linezolid for the treatment of adults with bone and joint infections. *Int J Antimicrob Agents*. 2007 Mar;29(3):233-9.
168. Bassetti M, Righi E, Di Biagio A, Rosso R, Beltrame A, Bassetti D. Role of linezolid in the treatment of orthopedic infections. *Expert Rev Anti Infect Ther*. 2005 Jun;3(3):343-52.
169. Brouqui P, Rousseau MC, Stein A, Drancourt M, Raoult D. Treatment of *Pseudomonas aeruginosa*-infected orthopedic prostheses with ceftazidime-ciprofloxacin antibiotic combination. *Antimicrob Agents Chemother*. 1995 Nov;39(11):2423-5.
170. Haagensen JAJ, Klausen M, Ernst RK, Miller SI, Folkesson A, Tolker-Nielsen T, et al. Differentiation and distribution of colistin- and sodium dodecyl sulfate-tolerant cells in *Pseudomonas aeruginosa* biofilms. *J Bacteriol*. 2007 Jan;189(1):28-37.
171. Pamp SJ, Gjermansen M, Johansen HK, Tolker-Nielsen T. Tolerance to the antimicrobial peptide colistin in *Pseudomonas aeruginosa* biofilms is linked to metabolically active cells, and depends on the pmr and mexAB-oprM genes. *Mol Microbiol*. 2008 Apr;68(1):223-40.
172. Folkesson A, Haagensen JAJ, Zampaloni C, Sternberg C, Molin S. Biofilm induced tolerance towards antimicrobial peptides. *PLoS One*. 2008 Apr 2;3(4):e1891.
173. Hancock RE, Wong PG. Compounds which increase the permeability of the *Pseudomonas aeruginosa* outer membrane. *Antimicrob Agents Chemother*. 1984 Jul;26(1):48-52.
174. Hancock RE. Peptide antibiotics. *Lancet*. 1997 Feb 8;349(9049):418-22.
175. Corvec S, Furustrand T, Ulfarsson U, Betrisey B, Borens O, Trampuz A. Activities of fosfomicin, tigecycline, colistin, and gentamicin against extended-spectrum- β -lactamase-producing *Escherichia coli* in a foreign-body infection model. *Antimicrob Agents Chemother*. 2013 Mar;57(3):1421-7.
176. Lora-Tamayo J, Murillo O, Bergen PJ, Nation RL, Poudyal A, Luo X, et al. Activity of colistin combined with doripenem at clinically relevant concentrations against multidrug-resistant *Pseudomonas aeruginosa* in an in vitro dynamic biofilm model. *J Antimicrob Chemother*. 2014

Sep;69(9):2434-42.

177. Ribera A, Benavent E, Lora-Tamayo J, Tubau F, Pedrero S, Cabo X, et al. Osteoarticular infection caused by MDR *Pseudomonas aeruginosa*: the benefits of combination therapy with colistin plus β -lactams. *J Antimicrob Chemother.* 2015 Dec;70(12):3357-65.
178. Schintler MV, Traunmüller F, Metzler J, Kreuzwirt G, Spindel S, Mauric O, et al. High fosfomycin concentrations in bone and peripheral soft tissue in diabetic patients presenting with bacterial foot infection. *J Antimicrob Chemother.* 2009 Sep;64(3):574-8.
179. Rodríguez-Pardo D, Pigrau C, Corona PS, Almirante B. An update on surgical and antimicrobial therapy for acute periprosthetic joint infection: new challenges for the present and the future. *Expert Rev Anti Infect Ther.* 2015 Feb;13(2):249-65.
180. Berbari EF, Marculescu C, Sia I, Lahr BD, Hanssen AD, Steckelberg JM, et al. Culture-negative prosthetic joint infection. *Clin Infect Dis.* 2007 Nov 1;45(9):1113-9.
181. Malekzadeh D, Osmon DR, Lahr BD, Hanssen AD, Berbari EF. Prior use of antimicrobial therapy is a risk factor for culture-negative prosthetic joint infection. *Clin Orthop Relat Res.* 2010;468(8):2039-45.
182. Tande AJ, Patel R. Prosthetic joint infection. *Clin Microbiol Rev.* 2014 Apr;27(2):302-45.
183. Polk RE, Johnson CK, McClish D, Wenzel RP, Edmond MB. Predicting hospital rates of fluoroquinolone-resistant *Pseudomonas aeruginosa* from fluoroquinolone use in US hospitals and their surrounding communities. *Clin Infect Dis.* 2004 Aug 15;39(4):497-503.
184. MacDougall C, Powell JP, Johnson CK, Edmond MB, Polk RE. Hospital and community fluoroquinolone use and resistance in *Staphylococcus aureus* and *Escherichia coli* in 17 US hospitals. *Clin Infect Dis.* 2005 Aug 15;41(4):435-40.
185. Schindler M, Bernard L, Belaieff W, Gamulin A, Racloz G, Emonet S, et al. Epidemiology of adverse events and *Clostridium difficile*-associated diarrhea during long-term antibiotic therapy for osteoarticular infections. *J Infect.* 2013 Nov 1;67(5):433-8.
186. Valour F, Karsenty J, Bouaziz A, Ader F, Tod M, Lustig S, et al. Antimicrobial-related severe adverse events during treatment of bone and joint infection due to methicillin-susceptible *Staphylococcus aureus*. *Antimicrob Agents Chemother.* 2014;58(2):746-55.
187. Puhto A-P, Puhto T, Syrjala H. Short-course antibiotics for prosthetic joint infections treated with prosthesis retention. *Clin Microbiol Infect.* 2012 Nov;18(11):1143-8.

188. Lora-Tamayo J, Euba G, Cobo J, Horcajada J, Soriano A, Sandoval E, et al. Short vs. long duration of levofloxacin plus rifampin for acute staphylococcal prosthetic joint infection managed with implant retention: a randomised clinical trial. *Int J Antimicrob Agents*. 2016 Sep;48(3):310-6.
189. Piso RJ, Elke R. Antibiotic treatment can be safely stopped in asymptomatic patients with prosthetic joint infections despite persistent elevated C-reactive protein values. *Infection*. 2010 Aug;38(4):293-6.
190. Achermann Y, Stasch P, Preiss S, Lucke K, Vogt M. Characteristics and treatment outcomes of 69 cases with early prosthetic joint infections of the hip and knee. *Infection*. 2014 Jun;42(3):511-9.
191. Cabrita HB, Croci AT, Camargo OP de, Lima ALLM de. Prospective study of the treatment of infected hip arthroplasties with or without the use of an antibiotic-loaded cement spacer. *Clinics (Sao Paulo)*. 2007 Apr;62(2):99-108.
192. Hoad-Reddick DA, Evans CR, Norman P, Stockley I. Is there a role for extended antibiotic therapy in a two-stage revision of the infected knee arthroplasty? *J Bone Joint Surg Br*. 2005 Feb;87(2):171-4.
193. Hart WJ, Jones RS. Two-stage revision of infected total knee replacements using articulating cement spacers and short-term antibiotic therapy. *J Bone Joint Surg Br*. 2006 Aug;88(8):1011-5.
194. Stockley I, Mockford BJ, Hoad-Reddick A, Norman P. The use of two-stage exchange arthroplasty with depot antibiotics in the absence of long-term antibiotic therapy in infected total hip replacement. *J Bone Joint Surg Br*. 2008 Feb;90(2):145-8.
195. Whittaker JP, Warren RE, Jones RS, Gregson PA. Is prolonged systemic antibiotic treatment essential in two-stage revision hip replacement for chronic Gram-positive infection? *J Bone Joint Surg Br*. 2009 Jan;91(1):44-51.
196. Hsieh P-H, Huang K-C, Lee P-C, Lee MS. Two-stage revision of infected hip arthroplasty using an antibiotic-loaded spacer: retrospective comparison between short-term and prolonged antibiotic therapy. *J Antimicrob Chemother*. 2009 Aug;64(2):392-7.
197. McKenna PB, O'Shea K, Masterson EL. Two-stage revision of infected hip arthroplasty using a shortened post-operative course of antibiotics. *Arch Orthop Trauma Surg*. 2009 Apr;129(4):489-94.
198. Kuzyk PRT, Dhotar HS, Sternheim A, Gross AE, Safir O, Backstein D. Two-stage revision arthroplasty for management of chronic periprosthetic hip and knee infection: techniques, controversies, and outcomes. *J Am Acad Orthop Surg*. 2014 Mar;22(3):153-64.

199. Sendi P, Rohrbach M, Graber P, Frei R, Ochsner PE, Zimmerli W. Staphylococcus aureus small colony variants in prosthetic joint infection. *Clin Infect Dis*. 2006 Oct 15;43(8):961-7.
200. Murillo O, Euba G, Calatayud L, Domínguez MA, Verdaguer R, Pérez A, et al. The role of intraoperative cultures at the time of reimplantation in the management of infected total joint arthroplasty. *Eur J Clin Microbiol Infect Dis*. 2008 Sep;27(9):805-11.
201. Cabo J, Euba G, Saborido A, González-Panisello M, Domínguez MA, Agulló JL, et al. Clinical outcome and microbiological findings using antibiotic-loaded spacers in two-stage revision of prosthetic joint infections. *J Infect*. 2011 Jul;63(1):23-31.
202. Fink B, Grossmann A, Fuerst M, Schäfer P, Frommelt L. Two-stage cementless revision of infected hip endoprostheses. *Clin Orthop Relat Res*. 2009 Jul;467(7):1848-58.
203. Cordero-Ampuero J, Esteban J, García-Cimbrelo E. Oral antibiotics are effective for highly resistant hip arthroplasty infections. *Clin Orthop Relat Res*. 2009 Sep;467(9):2335-42.
204. Darley ESR, Bannister GC, Blom AW, Macgowan AP, Jacobson SK, Alfouzan W. Role of early intravenous to oral antibiotic switch therapy in the management of prosthetic hip infection treated with one- or two-stage replacement. *J Antimicrob Chemother*. 2011 Oct;66(10):2405-8.
205. Silvestre A, Almeida F, Renovell P, Morante E, López R. Revision of infected total knee arthroplasty: two-stage reimplantation using an antibiotic-impregnated static spacer. *Clin Orthop Surg*. 2013 Sep;5(3):180-7.
206. Cobo J, Lora-Tamayo J, Euba G, Jover-Sáenz A, Palomino J, del Toro M, et al. Linezolid in late-chronic prosthetic joint infection caused by gram-positive bacteria. *Diagn Microbiol Infect Dis*. 2013 May;76(1):93-8.
207. Sorli L, Puig L, Torres-Claramunt R, González A, Alier A, Knobel H, et al. The relationship between microbiology results in the second of a two-stage exchange procedure using cement spacers and the outcome after revision total joint replacement for infection: the use of sonication to aid bacteriological analysis. *J Bone Joint Surg Br*. 2012 Feb;94(2):249-53.
208. Romanò CL, Romanò D, Albisetti A, Meani E. Preformed antibiotic-loaded cement spacers for two-stage revision of infected total hip arthroplasty. Long-term results. *Hip Int*. 2012 Jul;22 Suppl 8(S8):S46-53.
209. Joseph TN, Chen AL, Di Cesare PE. Use of antibiotic-impregnated

- cement in total joint arthroplasty. *J Am Acad Orthop Surg*. 2003 Jan;11(1):38-47.
210. Degen RM, Davey JR, Davey JR, Howard JL, McCalden RW, Naudie DDR. Does a prefabricated gentamicin-impregnated, load-bearing spacer control periprosthetic hip infection? *Clin Orthop Relat Res*. 2012 Oct;470(10):2724-9.
211. Fink B, Vogt S, Reinsch M, Büchner H. Sufficient release of antibiotic by a spacer 6 weeks after implantation in two-stage revision of infected hip prostheses. *Clin Orthop Relat Res*. 2011 Nov;469(11):3141-7.
212. Regis D, Sandri A, Samaila E, Benini A, Bondi M, Magnan B. Release of gentamicin and vancomycin from preformed spacers in infected total hip arthroplasties: measurement of concentrations and inhibitory activity in patients' drainage fluids and serum. *ScientificWorldJournal*. 2013;2013(4):752184-6.
213. Gálvez-López R, Peña-Monje A, Antelo-Lorenzo R, Guardia-Olmedo J, Moliz J, Hernández-Quero J, et al. Elution kinetics, antimicrobial activity, and mechanical properties of 11 different antibiotic loaded acrylic bone cement. *Diagn Microbiol Infect Dis*. 2014 Jan;78(1):70-4.
214. Schurman DJ, Trindade C, Hirshman HP, Moser K, Kajiyama G, Stevens P. Antibiotic-acrylic bone cement composites. Studies of gentamicin and Palacos. *J Bone Joint Surg*. 1978 Oct;60(7):978-84.
215. Wahlig H, Dingeldein E. Antibiotics and bone cements. Experimental and clinical long-term observations. *Acta Orthop Scand*. 1980 Feb;51(1):49-56.
216. Murray WR. Use of antibiotic-containing bone cement. *Clin Orthop Relat Res*. 1984 Nov;(190):89-95.
217. Adams K, Couch L, Cierny G, Calhoun J, Mader JT. In vitro and in vivo evaluation of antibiotic diffusion from antibiotic-impregnated polymethylmethacrylate beads. *Clin Orthop Relat Res*. 1992 May;(278):244-52.
218. Neut D, de Groot EP, Kowalski RSZ, van Horn JR, van der Mei HC, Busscher HJ. Gentamicin-loaded bone cement with clindamycin or fusidic acid added: biofilm formation and antibiotic release. *J Biomed Mater Res A*. 2005 May 1;73(2):165-70.
219. Anagnostakos K, Kelm J, Grün S, Schmitt E, Jung W, Swoboda S. Antimicrobial properties and elution kinetics of linezolid-loaded hip spacers in vitro. *J Biomed Mater Res Part B Appl Biomater*. 2008 Oct;87(1):173-8.
220. Howlin RP, Brayford MJ, Webb JS, Cooper JJ, Aiken SS, Stoodley P. Antibiotic-loaded synthetic calcium sulfate beads for prevention of

bacterial colonization and biofilm formation in periprosthetic infections. *Antimicrob Agents Chemother.* 2015 Jan;59(1):111-20.

221. Kendall RW, Duncan CP, Smith JA, Ngui-Yen JH. Persistence of bacteria on antibiotic loaded acrylic depots. A reason for caution. *Clin Orthop Relat Res.* 1996 Aug;(329):273-80.
222. Corona PS, Espinal L, Rodríguez-Pardo D, Pigrau C, Larrosa N, Flores X. Antibiotic susceptibility in gram-positive chronic joint arthroplasty infections: increased aminoglycoside resistance rate in patients with prior aminoglycoside-impregnated cement spacer use. *J Arthroplasty.* 2014 Aug;29(8):1617-21.
223. Koo KH, Yang JW, Cho SH, Song HR, Park HB, Ha YC, et al. Impregnation of vancomycin, gentamicin, and cefotaxime in a cement spacer for two-stage cementless reconstruction in infected total hip arthroplasty. *J Arthroplasty.* 2001 Oct;16(7):882-92.
224. Frada T, Martínez-Pastor JC, Bori G, Tornero E, JM S, Bosch J, et al. Clinical relevance of microbiological positive cultures on two stage infected arthroplasty revision: A retrospective study. *EFFORT*, May-2015 Prague.
225. Luu A, Syed F, Raman G, Bhalla A, Muldoon E, Hadley S, et al. Two-stage arthroplasty for prosthetic joint infection: a systematic review of acute kidney injury, systemic toxicity and infection control. *J Arthroplasty.* 2013 Oct;28(9):1490-1.
226. Chen AF, Parvizi J. Antibiotic-loaded bone cement and periprosthetic joint infection. *J Long Term Eff Med Implants.* 2014;24(2-3):89-97.
227. Chiang E-R, Su Y-P, Chen T-H, Chiu F-Y, Chen W-M. Comparison of articulating and static spacers regarding infection with resistant organisms in total knee arthroplasty. *Acta Orthop.* 2011 Aug;82(4):460-4.
228. Rand JA, Bryan RS. Reimplantation for the salvage of an infected total knee arthroplasty. *J Bone Joint Surg.* 1983 Oct;65(8):1081-6.
229. Hanssen AD, Rand JA, Osmon DR. Treatment of the infected total knee arthroplasty with insertion of another prosthesis. The effect of antibiotic-impregnated bone cement. *Clin Orthop Relat Res.* 1994 Dec;(309):44-55.
230. Segawa H, Tsukayama DT, Kyle RF, Becker DA, Gustilo RB. Infection after total knee arthroplasty. A retrospective study of the treatment of eighty-one infections. *J Bone Joint Surg.* 1999 Oct;81(10):1434-45.
231. Brandt CM, Duffy MC, Berbari EF, Hanssen AD, Steckelberg JM, Osmon DR. *Staphylococcus aureus* prosthetic joint infection treated with prosthesis removal and delayed reimplantation arthroplasty. *JMCP.*

- 1999 Jun;74(6):553-8.
232. Westrich GH, Walcott-Sapp S, Bornstein LJ, Bostrom MP, Windsor RE, Brause BD. Modern treatment of infected total knee arthroplasty with a 2-stage reimplantation protocol. *J Arthroplasty*. 2010 Oct;25(7):1015-21, 1021.e1-2.
233. Bejon P, Berendt A, Atkins BL, Green N, Parry H, Masters S, et al. Two-stage revision for prosthetic joint infection: predictors of outcome and the role of reimplantation microbiology. *J Antimicrob Chemother*. 2010 Mar;65(3):569-75.
234. Larsson S, Thelander U, Friberg S. C-reactive protein (CRP) levels after elective orthopedic surgery. *Clin Orthop Relat Res*. 1992 Feb;(275):237-42.
235. Ghanem E, Azzam K, Seeley M, Joshi A, Parvizi J. Staged revision for knee arthroplasty infection: what is the role of serologic tests before reimplantation? *Clin Orthop Relat Res*. 2009 Jul;467(7):1699-705.
236. Kusuma SK, Ward J, Jacofsky M, Sporer SM, Valle Della CJ. What is the role of serological testing between stages of two-stage reconstruction of the infected prosthetic knee? *Clin Orthop Relat Res*. 2011 Apr;469(4):1002-8.
237. Shukla SK, Ward JP, Jacofsky MC, Sporer SM, Paprosky WG, Valle Della CJ. Perioperative testing for persistent sepsis following resection arthroplasty of the hip for periprosthetic infection. *J Arthroplasty*. 2010 Sep;25(6 Suppl):87-91.
238. Mont MA, Waldman BJ, Hungerford DS. Evaluation of preoperative cultures before second-stage reimplantation of a total knee prosthesis complicated by infection. A comparison-group study. *J Bone Joint Surg*. 2000 Nov;82-A(11):1552-7.
239. Lonner JH, Siliski JM, Valle Della C, DiCesare P, Lotke PA. Role of knee aspiration after resection of the infected total knee arthroplasty. *Am J Orthop*. 2001 Apr;30(4):305-9.
240. Esteban J, Sorlí L, Alentorn-Geli E, Puig L, Horcajada JP. Conventional and molecular diagnostic strategies for prosthetic joint infections. *Expert Rev Mol Diagn*. 2014 Jan;14(1):83-96.
241. Spangehl MJ, Masri BA, O'Connell JX, Duncan CP. Prospective analysis of preoperative and intraoperative investigations for the diagnosis of infection at the sites of two hundred and two revision total hip arthroplasties. *J Bone Joint Surg*. 1999 May;81(5):672-83.
242. Lonner JH. Identifying ongoing infection after resection arthroplasty and before second-stage reimplantation. *Am J Knee Surg*. 2001;14(1):68-71.

243. Murillo O, Doménech A, Euba G, Verdaguer R, Tubau F, Cabo J, et al. Efficacy of linezolid alone and in combination with rifampin in staphylococcal experimental foreign-body infection. *J Infect.* 2008 Sep;57(3):229-35.
244. Pagnano MW, Trousdale RT, Hanssen AD. Outcome after reinfection following reimplantation hip arthroplasty. *Clin Orthop Relat Res.* 1997 May;(338):192-204.
245. Van Eldere J, Peetermans WE, Struelens M, Deplano A, Bobbaers H. Polyclonal staphylococcal endocarditis caused by genetic variability. *Clin Infect Dis.* 2000 Jul;31(1):24-30.
246. Atkins BL, Athanasou N, Deeks JJ, Crook DW, Simpson H, Peto TE, et al. Prospective evaluation of criteria for microbiological diagnosis of prosthetic-joint infection at revision arthroplasty. The OSIRIS Collaborative Study Group. *J Clin Microbiol.* 1998 Oct;36(10):2932-9.
247. Buttaro M, Valentini R, Piccaluga F. Persistent infection associated with residual cement after resection arthroplasty of the hip. *Acta Orthop Scand.* 2004 Aug;75(4):427-9.
248. Nelson CL, Jones RB, Wingert NC, Foltzer M, Bowen TR. Sonication of antibiotic spacers predicts failure during two-stage revision for prosthetic knee and hip infections. *Clin Orthop Relat Res.* 2014 Jul;472(7):2208-14.
249. AlBuhairan B, Hind D, Hutchinson A. Antibiotic prophylaxis for wound infections in total joint arthroplasty: a systematic review. *J Bone Joint Surg Br.* 2008 Jul;90(7):915-9.
250. Zywiell MG, Johnson AJ, Stroh DA, Martin J, Marker DR, Mont MA. Prophylactic oral antibiotics reduce reinfection rates following two-stage revision total knee arthroplasty. *Int Orthop.* 2011 Jan;35(1):37-42.
251. Johnson AJ, Zywiell MG, Jones LC, Delanois RE, Stroh DA, Mont MA. Reduced re-infection rates with postoperative oral antibiotics after two-stage revision hip arthroplasty. *BMC Musculoskelet Disord.* 2013;14(1):123.
252. Azzam K, McHale K, Austin M, Purtill JJ, Parvizi J. Outcome of a second two-stage reimplantation for periprosthetic knee infection. *Clin Orthop Relat Res.* 2009 Jul;467(7):1706-14.
253. Kalra KP, Lin KK, Bozic KJ, Ries MD. Repeat 2-stage revision for recurrent infection of total hip arthroplasty. *J Arthroplasty.* 2010 Sep;25(6):880-4.
254. Kubista B, Hartzler RU, Wood CM, Osmon DR, Hanssen AD, Lewallen DG. Reinfection after two-stage revision for periprosthetic infection of

- total knee arthroplasty. *Int Orthop*. 2012 Jan;36(1):65-71.
255. Göksan SB, Freeman MA. One-stage reimplantation for infected total knee arthroplasty. *J Bone Joint Surg Br*. 1992 Jan;74(1):78-82.
256. Freeman MA, Sudlow RA, Casewell MW, Radcliff SS. The management of infected total knee replacements. *J Bone Joint Surg Br*. 1985 Nov;67(5):764-8.
257. Bratzler DW, Dellinger EP, Olsen KM, Perl TM, Auwaerter PG, Bolon MK, et al. Clinical practice guidelines for antimicrobial prophylaxis in surgery. *Am J Health Syst Pharm*. 2013 Feb 1;70(3):195-283.
258. Ghanem E, Parvizi J, Clohisy J, Burnett S, Sharkey PF, Barrack R. Perioperative antibiotics should not be withheld in proven cases of periprosthetic infection. *Clin Orthop Relat Res*. 2007 Aug;461:44-7.
259. Burnett RSJ, Aggarwal A, Givens SA, McClure JT, Morgan PM, Barrack RL. Prophylactic antibiotics do not affect cultures in the treatment of an infected TKA: a prospective trial. *Clin Orthop Relat Res*. 2010 Jan;468(1):127-34.
260. Swoboda SM, Merz C, Kostuik J, Trentler B, Lipsett PA. Does intraoperative blood loss affect antibiotic serum and tissue concentrations? *Arch Surg*. 1996 Nov;131(11):1165-71; discussion 1171-2.
261. Kendoff D, Gehrke T. Surgical management of periprosthetic joint infection: one-stage exchange. *J Knee Surg*. 2014 Aug;27(4):273-8.
262. Barrack RL, Aggarwal A, Burnett RSJ, Clohisy JC, Ghanem E, Sharkey P, et al. The fate of the unexpected positive intraoperative cultures after revision total knee arthroplasty. *J Arthroplasty*. 2007 Sep;22(6 Suppl 2):94-9.
263. Saleh A, Guirguis A, Klika AK, Johnson L, Higuera CA, Barsoum WK. Unexpected positive intraoperative cultures in aseptic revision arthroplasty. *J Arthroplasty*. 2014 Nov;29(11):2181-6.
264. Marculescu CE, Berbari EF, Hanssen AD, Steckelberg JM, Osmon DR. Prosthetic joint infection diagnosed postoperatively by intraoperative culture. *Clin Orthop Relat Res*. 2005 Oct;439:38-42.
265. Song J-U, Park HY, Jeon K, Um S-W, Kwon OJ, Koh W-J. Treatment of thoracic actinomycosis: A retrospective analysis of 40 patients. *Ann Thorac Med*. 2010 Apr;5(2):80-5.
266. Choi J, Koh W-J, Kim TS, Lee KS, Han J, Kim H, et al. Optimal duration of IV and oral antibiotics in the treatment of thoracic actinomycosis. *Chest*. 2005 Oct;128(4):2211-7.

267. Kolditz M, Bickhardt J, Matthiessen W, Holotiuk O, Höffken G, Koschel D. Medical management of pulmonary actinomycosis: data from 49 consecutive cases. *J Antimicrob Chemother.* 2009 Apr;63(4):839-41.
268. Gener G, Canoui-Poitrine F, Revuz JE, Faye O, Poli F, Gabison G, et al. Combination therapy with clindamycin and rifampicin for hidradenitis suppurativa: a series of 116 consecutive patients. *Dermatology (Basel).* 2009;219(2):148-54.
269. Samad El Y, Havet E, Bentayeb H, Olory B, Canarelli B, Lardanchet J-F, et al. [Treatment of osteoarticular infections with clindamycin in adults]. *Med Mal Infect.* 2008 Sep;38(9):465-70.
270. Walker AS, Ford D, Gilks CF, Munderi P, Ssali F, Reid A, et al. Daily cotrimoxazole prophylaxis in severely immunosuppressed HIV-infected adults in Africa started on combination antiretroviral therapy: an observational analysis of the DART cohort. *Lancet.* 2010 Apr 10;375(9722):1278-86.
271. Antoniou T, Gomes T, Juurlink DN, Loutfy MR, Glazier RH, Mamdani MM. Trimethoprim-sulfamethoxazole-induced hyperkalemia in patients receiving inhibitors of the renin-angiotensin system: a population-based study. *Arch Intern Med.* 2010 Jun 28;170(12):1045-9.
272. Antoniou T, Hollands S, Macdonald EM, Gomes T, Mamdani MM, Juurlink DN, et al. Trimethoprim-sulfamethoxazole and risk of sudden death among patients taking spironolactone. *CMAJ.* 2015 Mar 3;187(4):E138-43.
273. Van der Veen EL, Schilder AGM, Timmers TK, Rovers MM, Fluit AC, Bonten MJ, et al. Effect of long-term trimethoprim/sulfamethoxazole treatment on resistance and integron prevalence in the intestinal flora: a randomized, double-blind, placebo-controlled trial in children. *J Antimicrob Chemother.* 2009 May;63(5):1011-6.
274. Albert RK, Connett J, Bailey WC, Casaburi R, Cooper JAD, Criner GJ, et al. Azithromycin for prevention of exacerbations of COPD. *N Engl J Med.* 2011 Aug 25;365(8):689-98.
275. Herath SC, Poole P. Prophylactic antibiotic therapy for chronic obstructive pulmonary disease (COPD). *Cochrane Database Syst Rev.* 2013 Nov 28;(11):CD009764.
276. Ray WA, Murray KT, Hall K, Arbogast PG, Stein CM. Azithromycin and the risk of cardiovascular death. *N Engl J Med.* 2012 May 17;366(20):1881-90.
277. Albert RK, Schuller JL, COPD Clinical Research Network. Macrolide antibiotics and the risk of cardiac arrhythmias. *Am J Respir Crit Care Med.* 2014 May 15;189(10):1173-80.

278. Yew WW, Chan CK, Leung CC, Chau CH, Tam CM, Wong PC, et al. Comparative roles of levofloxacin and ofloxacin in the treatment of multidrug-resistant tuberculosis: preliminary results of a retrospective study from Hong Kong. *Chest*. 2003 Oct;124(4):1476-81.
279. Wise BL, Peloquin C, Choi H, Lane NE, Zhang Y. Impact of age, sex, obesity, and steroid use on quinolone-associated tendon disorders. *Am J Med*. 2012 Dec;125(12):1228.e23-8.
280. Geria AN, Tajirian AL, Kihiczak G, Schwartz RA. Minocycline-induced skin pigmentation: an update. *Acta Dermatovenerol Croat*. 2009;17(2):123-6.
281. Goulden V, Glass D, Cunliffe WJ. Safety of long-term high-dose minocycline in the treatment of acne. *Br J Dermatol*. 1996 Apr;134(4):693-5.
282. Garner SE, Eady A, Bennett C, Newton JN, Thomas K, Popescu CM. Minocycline for acne vulgaris: efficacy and safety. *Cochrane Database Syst Rev*. 2012 Aug 15;(8):CD002086.

Tables

Table 1

System from rankings recommendations in clinical guidelines¹⁴

Level of scientific evidence	
I	Evidence obtained from ≥ 1 randomized clinical trial
II	Evidence obtained from ≥ 1 well-designed non-randomized clinical trial, or cohort studies, or case-control-studies, especially if they have been performed in more than one centre, from multiple time-series; or from dramatic results for uncontrolled experiments.
III	Evidence obtained from documents or opinions of experts, based in clinical experience descriptive studies or reports of expert committees
Grades of recommendation	
A	Good evidence to recommend the use of a measure or practice
B	Moderate evidence to recommend the use of a measure or practice
C	Poor evidence to recommend the use of a measure or practice
D	Moderate evidence to discourage the use of a measure or practice
E	Good evidence to discourage the use of a measure or practice

Table 2
Classifications of prosthetic joint infections (PJI)

Author	Type of PJI	Definition
Tsukayama ^{22,230}	Early post-surgical	Symptoms of infection begin within the first month after the placement of the prosthesis
	Late chronic	Symptoms of infection begin insidiously beyond the first month after the placement of the prosthesis
	Hematogenous	Symptoms of the infection emerge acutely as a consequence of a bloodstream infection (either suspected or proven)
	Positive intraoperative cultures	≥2 positive intraoperative cultures taken during a 1-step exchange procedure for an assumed aseptic prosthetic loosening
Zimmerli ⁶	Early	Symptoms of infection emerge within the first 3 months after the placement of the prosthesis
	Delayed	Symptoms of infection begin within 3 months and 2 years after the placement of the prosthesis
	Late	The infection occurs beyond 2 years after the placement of the prosthesis, as a consequence of a

		bloodstream infection (either suspected or proven)
--	--	--

Comment: Tsukayama's categories *positive intraoperative cultures* (PIOC) and *late-chronic* infection actually reflect the same clinical scenario: a loosened prosthesis inserted months or years previously, the difference being that, at the time of diagnosis, in the PIOC category a new prosthesis has already substituted the infected one (the surgeon did not observed signs of infections during surgery).

Also, these categories are equivalent (except for the limitation in the calendar) to Zimmerli's *Delayed* category. Finally, Tsukayama's *hematogenous* category has the same definition as Zimmerli's *late* category (again, except for the time limit, set at 2 years). From a practical point of view, early post-surgical infections and hematogenous infections (*late*, according to Zimmerli's classification) may be considered as acute infections, whereas *late chronic* and *delayed* PJI correspond to chronic infections.

Table 3

Selection of representative cohorts of patients with prosthetic joint infection managed with implant retention

Ref	Centers	Patients submitted to DAIR	Success	Significant parameters and comments	Time to failure
Schoifet, 1990 ²³	One center	N = 31 TKP, various microorg.	23%	Predictors of failure: <i>S. aureus</i> , age, duration of symptoms	252 days (max 1008 days)
Burger, 1991 ²⁴	One center	N = 39 TKP, various microorg.	18%	Predictors of success: short duration of symptoms, susceptible microorganisms, no radiological signs of infection, no problems of the surgical wound	
Tsukayama, 1996 ²²	One center	N = 41 THP, 90% <i>Staphylococcus</i>	68%	Predictors of failure: non-cemented prosthesis, hematogenous infections	
Brandt, 1997 ²⁵	One center	N = 33, all <i>S. aureus</i>	31%	Predictors of failure: duration of symptoms >2 days	81 days (range 15-614)
Tattevin, 1999 ²⁶	One center	N = 34, various microorg. (74% <i>S. aureus</i>)	38%	Predictors of failure: duration of symptoms	
Meehan, 2003 ²⁷	One center	N = 19, all <i>S. agalactiae</i>	89%	8 cases treated with SAT (if considered as failures, 53% global success)	At 114 and 204 days
Berdal, 2005 ²⁸	One center	N = 29 early infections (<3 months). Various microorg. (60% <i>S. aureus</i>)	83%	Treatment protocol based in the combination of ciprofloxacin + rifampin	Mean 97 days, max 217 days
Everts, 2004 ²⁹	One center	N = 16, all streptococci	94%	Very long treatments, SAT in some patients	
Barberan, 2006 ³⁰	One center	N = 60, all staphylococci	65%	Predictors of failure: duration of symptoms >6 months	
Marculescu, 2006 ³¹	One center	N = 99, various microorg.	46%	Predictors of failure: sinus tract, duration of symptoms >7 days. Most patients treated for very long times, SAT in some cases	
Soriano, 2006 ³²	One center	N = 47, various microorg.	77%	Predictors of failure: infection by methicillin-resistant <i>S. aureus</i> or by enterococci	
Aboltins, 2007 ³³	One center	N = 20, all <i>S. aureus</i>	90%	Treatment protocol based on the combination of rifampin plus fusidic acid	
Byren, 2009 ²⁰	One center	N = 112, various microorg.	82%	Predictors of failure: debridement performed by arthroscopy, revision prosthesis, infection by <i>S. aureus</i>	Most failures happened within the first 4 months after antibiotic withdrawal
Hsieh, 2009 ³⁴	One center	N = 27, all Gram-negative microorg.	26%	Large cohort of PJI, including a minority of patients treated with DAIR. Poorer prognosis in patients with a long duration of symptoms	
Martínez-Pastor, 2009 ³⁵	One center	N = 47, all Gram-negative microorg.	75%	Predictors of failure: high C-reactive protein, fluoroquinolone-resistant microorg.	
Rodríguez-Pardo, 2010 ³⁶	Multi-center	N = 34 hematogenous cases, various microorg.	56%	Predictors of success: infection caused by streptococci or Gram-negative bacilli	
Senneville, 2011 ³⁷	One center	N = 41, all <i>S. aureus</i>	78%	Majority use of fluoroquinolones and rifampin (94%)	165 days after antibiotic withdrawal
Cobo, 2011 ³⁸	Multi-center	N = 117 early infections (<1 month), various microorg.	57%	Predictors of failure: infection caused by <i>S. aureus</i> and cases attended at one particular center	
Aboltins, 2011 ³⁹	One center	N = 17, all Gram-negative microorg.	94%	Protocol of treatment based on the use of fluoroquinolones	
Vílchez, 2011 ⁴⁰	One center	N = 53, all <i>S. aureus</i> , acute post-surgical cases	76%	Predictors of failure: C-reactive protein >220 mg/L and the need for a second debridement	
Zmistowski, 2011 ⁴¹	One center	N = 103, 86% <i>S. aureus</i> .	46%	Predictors of success: infection caused by Gram-negative bacilli	
Sendi, 2011 ¹⁵⁷	Multi-center	N = 20, all <i>S. agalactiae</i>	65%	Better prognosis in patients meeting Zimmerli's criteria for undergoing DAIR	
Geurts, 2013 ⁴⁷	One center	N = 89, various microorg.	83%	Predictors of failure: prosthesis age >4 weeks at the time of debridement. The management included the use of beads loaded with antibiotics	

Lora-Tamayo, 2013 ⁴³	Multi-center	N = 345, all <i>S. aureus</i>	55%	Predictors of failure: immunosuppression, bacteremia, high C-reactive protein, polymicrobial infection, need for a 2 nd debridement, and not exchanging the removable components	130 days after the end of therapy (max 2528)
Achermann, 2014 ¹⁹⁰	One center	N = 55, various microorg. Early infections (<3 months)	80%		Median 219 days (max 329 days)
Ascione, 2015 ¹³⁰	One center	N = 159, various microorg.	80%		14-63 days after the end of therapy

DAIR: debridement, antibiotics and implant retention; Microorg: microorganism; SAT: suppressive antimicrobial therapy; THP: total hip prosthesis; TKP: total knee prosthesis.

Table 4

Published studies evaluating the efficacy of a 1-step exchange procedure for management of prosthetic joint infection

Author (year)	N	Joint	Local antibiotics	Failure rate (%)	Follow-up
Tibrewal (2014) ⁶²	50	Knee	Yes	8	126 months
Singer (2012) ⁶³	63	Knee	Yes	5	36 months
Buechel (2004) ⁶⁴	21	Knee	Yes	9	122.4 months
Göksan (1992) ²⁵⁵	18	Knee	Yes	11	60 months
Freeman (1985) ²⁵⁶	8	Knee	Yes	0	12-40 months
Von Foerster (1991) ⁶⁵	104	Knee	Yes	27	75,5 months
Jenny (2014) ⁶⁶	65	Hip	Yes	16,9	37 months
Choi (2013) ⁶⁷	17	Hip	Yes	17,6	62 months
Loty (1992) ⁶⁸	90	Hip	Yes	17,7	47.3 months
Sanzén (1988) ⁶⁹	78	Hip	Yes	23,6	71 months
Wroblewski (1986) ⁷⁰	102	Hip	Yes	8,8	38 months
Buchholz (1981) ⁷¹	583	Hip	Yes	23,1	52 months
Carlsson (1978) ⁷²	59	Hip	Yes	8,4	24 months
Rudelli (2008) ⁷³	26	Hip	Yes	7,8	42-125 months
Mulcahy (1996) ⁷⁴	15	Hip	Yes	0	24-84 months
Callaghan (1999) ⁷⁵	24	Hip	Yes	8,3	1-14 years
Hope (1989) ⁷⁶	72	Hip	Yes	12,5	5-121 months
Ure (1998) ⁷⁷	20	Hip	Yes	0	3.5-17.1 months
Raut (1995) ⁷⁸	183	Hip	Yes	15,8	2-13 years
Yoo (2009) ⁷⁹	12	Hip	No	16,6	7.2 years
Bori (2014) ⁸⁰	24	Hip	No	4,1	44.6 months
Winkler (2008) ⁸¹	37	Hip	Yes	8,1	4.4 years

Winkler (2012) ⁸²	54	Hip	Yes	9,2	8 years
Zeller (2014) ⁸³	157	Hip	No	5	41.6 months
Klouche (2012) ⁸⁴	38	Hip	No	0	NA
Rudelli (2008) ⁷³	6	Hip	No	0	138 months
Sofer (2005) ⁸⁵	15	Knee and hip	Yes	7	18.4 months
Drancourt (1993) ⁸⁶	19	Knee and hip	NA	10.5	9-61 months

NA: not available.

Table 5

Empirical and targeted antimicrobial therapy in the eradication attempt of management with implant retention

	Recommended therapy	Alternative in patients allergic to β -lactams	Recommended duration
Initial phase of treatment (planktonic bacteria)			
Empirical treatment			
	Vancomycin or daptomycin or cloxacillin iv ^{&} + ceftazidime or cefepime or meropenem iv	Vancomycin or daptomycin iv + aztreonam iv	Until the results of cultures are available
Targeted treatment			
MSSA/MSSE*	(Cloxacillin or cefalozin) \pm daptomycin iv	Daptomycin + fosfomycin iv	7-14 days
MRSA/MRSE*	Vancomycin (alone) or daptomycin + (cloxacillin or fosfomycin) iv	Daptomycin + fosfomycin iv	7-14 days
<i>Streptococcus</i> spp	Ceftriaxone or penicillin iv	Vancomycin iv	7 days
<i>E. faecalis</i>	Ampicillin \pm ceftriaxone iv	Vancomycin or teicoplanin iv	7 days
Gram-negative bacilli	β -lactam iv ^{** †}	Ciprofloxacin iv	7 days
*consider adding rifampin after the 5 th day of treatment			
** consider combining an anti-pseudomonal β -lactam plus ciprofloxacin in PJI caused by <i>P. aeruginosa</i>			
Sequential phase treatment (biofilm-embedded bacteria)			
<i>Staphylococcus</i> spp			
Treatment of choice			

	Rifampin + levofloxacin po	-	Until completing 8 weeks
Alternatives without fluoroquinolones	Rifampin po + (daptomycin or fosfomycin) iv	-	2-4 weeks, then oral treat.
	Rifampin + (LNZ, fusidic, CMX, clindamycin, or minocyclin) po	-	Until completing 8 weeks of treat.
Alternatives without rifampin	Daptomycin iv + (fosfomycin or cloxacillin) iv	-	2-6 weeks, then oral treat.
	Daptomycin iv + (LNZ or CMX or levofloxacin) po	-	2-6 weeks, then oral treat.
	Levofloxacin + (LNZ, CMX, clindamycin or fusidic) po	-	Until completing 8 weeks of treat.
	LNZ + (CMX or fusidic) po	-	Until completing 8 weeks of treat.
	Clindamycin + fusidic po	-	Until completing 8 weeks of treat.
	Levofloxacin or moxifloxacin or CMX or LNZ po	-	Until completing 8 weeks of treat.
<i>Streptococcus spp</i>	(Ceftriaxone or penicillin iv) ± rifampin po	Vancomycin iv ± rifampin po	2-6 weeks, then oral treat.
	Amoxicillin ± rifampin po	Levofloxacin ± rifampin po	Until completing 8 weeks of treat.
	Levofloxacin ± rifampin po	-	Until completing 8 weeks of treat.
<i>E. faecalis</i>	Ampicillin ± ceftriaxone iv	Vancomycin or teicoplanin iv	2-6 weeks, then oral treat.
	Amoxicillin ± rifampin po	LNZ ± rifampin po	Until completing 8 weeks of treat.

<i>E. faecium</i>	Vancomycin or teicoplanin iv Linezolid po		2-6 weeks, then oral treat. Until completing 8 weeks of treat.
Gram-negative bacilli			
Treatment of choice	Ciprofloxacin po	-	Until completing 8 weeks of treat.
Alternatives without fluoroquinolones	β -lactam iv \pm colistin iv or β -lactam iv \pm fosfomicin iv CMX	Aztreonam iv \pm colistin iv -	6 weeks, then oral treat. Until completing 8 weeks of treat.
Alternatives against multi-drug resistant Gram-negative bacilli	β -lactam (CI) iv + colistin iv β -lactam (CI) iv + fosfomicin iv	Aztreonam iv (CI) + colistin iv	6 weeks

& The choice of a particular anti-staphylococcal agent may be conditioned by the presence of bloodstream infection, especially in hematogenous infections.

[†] The choice of a particular β -lactam agent against Gram-negative bacilli depends on the species and mechanisms of resistance: ceftriaxone is the treatment recommended for *Enterobacteriaceae*, except if they produce chromosomal β -lactamases (i.e., AmpC) or plasmidic extended-spectrum β -lactamases (ESBL); in these cases, the use of ertapenem will be preferred; in infections caused by *P. aeruginosa*, an anti-pseudomonal β -lactam is recommended.

Abbreviations: x: during; MRSA: methicillin-resistant *S. aureus*; MSSA: methicillin-susceptible *S. aureus*; MRSE: methicillin-resistant *S. epidermidis* (and other coagulase-negative staphylococci); MSSE: methicillin-susceptible *S. epidermidis* (and other coagulase-negative staphylococci). CMX: co-trimoxazole; Fusidic: fusidic acid; LNZ: linezolid; CI: continuous infusion; iv: intravenous treatment; po: *per os* (oral route); treat.: treatment.

Recommended doses (assuming normal renal function): cloxacillin, 2 g/4h iv; vancomycin, 1g/12h iv; daptomycin, 8-10 mg/kg/24h iv; ceftazidime, 2g/8h iv; aztreonam, 2g/8h iv; cefepime, 2g/8-12h iv; meropenem 1-2g/8h iv; ertapenem, 1g/24h iv; ceftriaxone 2g/24h; ampicillin: 2g/6h iv; amoxicillin, 1 g/8h po; rifampin, 600 mg/24h po; levofloxacin, 500-750 mg/24h po; moxifloxacin, 400 mg/24h po; ciprofloxacin, 400 mg/12h iv or 750-1000 mg/12h po; linezolid, 600 mg/12h po; fusidic acid, 500 mg/8h po; fosfomycin, 2 g/6h iv; colistin, 6-9 millions IU/d (8-12h) iv; co-trimoxazole 800/160 mg/8h po; clindamycin, 600 mg/6-8h po; minocycline, 200 mg/d po.

Table 6

Antimicrobials used in cement spacers

Fusidic acid
Amikacin
Amoxicillin
Amphotericin
Ampicillin
Aztreonam
Bacitracin
Cefazolin
Ceftazidim
Cefuroxim
Cephalothin
Cephmandole
Ciprofloxacin
Clindamycin
Colistin
Daptomycin
Erythromycin
Gentamicin
Lincomycin

Linezolid
Meropenem
Novobiocin
Oxacillin
Penicillin
Piperacillin-tazobactam
Polymyxin B
Streptomycin
Tazobactam
Ticarcillin
Tobramycin
Vancomycin
Voriconazol

Table 7

Antibiotics most frequently used as suppressive antimicrobial therapy (SAT)

	Experience in prolonged treatments	Precautions and main adverse events
Beta-lactams	Low toxicity in the treatment of actinomycoses ^{265,266} . However, hypersensitivity reactions are frequent with the use of penicillin ²⁶⁷ . β -lactams are the most frequently used antibiotics for SAT in various case series of PJI ^{91-93,99}	Skin rash, hypersensitivity reactions
Clindamycin	Very little experience has been reported: treatment of suppurative hidrosadenitis ²⁶⁸ and bone and joint infections ^{144,269} . Low toxicity	Skin rash. Digestive intolerance. <i>C. difficile</i> -associated colitis
Co-trimoxazole	There is a great deal of experience with its use; low toxicity is reported when low doses are used as prophylaxis of opportunistic infections ²⁷⁰ . The use of high doses in bone and joint infections has frequently led to discontinuation due to digestive intolerance ^{143,152}	Digestive intolerance, leukopenia, megaloblastic anemia, hypersensitivity reactions. Recently, cases of sudden death on patients being administered co-trimoxazole along with spironolactone or inhibitors of the renin-angiotensin system have been reported ^{271,272} . In a study addressing the impact of antimicrobials on fecal microbiota, a transitory increase of resistance to co-trimoxazole, amoxicillin, and amoxicillin-clavulanate acid was observed ²⁷³
Macrolides	There is experience of prolonged administration of macrolides for preventing infections in patients with chronic pulmonary obstructive disease, with infrequent adverse events ^{274,275}	A higher risk of sudden death in patients under treatment with macrolides plus amoxicillin has been reported ²⁷⁶ , although it has recently been questioned whether these patients may be affected by other circumstances that could prolong the QT segment ²⁷⁷

Fluoroquinolones	There is acceptable experience with the use of levofloxacin and ofloxacin in the treatment of multi-drug resistant tuberculosis (although the number of patients is scarce) ²⁷⁸	The use of fluoroquinolones has been associated with a higher risk of tendinopathy. This risk is increased in elderly patients, renal chronic failure and patients under treatment with corticosteroids ²⁷⁹
Rifampin	There is experience of long treatments with rifampin for brucellosis or tuberculosis. Short treatments of rifampin are more associated with toxicity	Rifampin must never be used alone due to a high risk of resistance. There are frequent drug-to-drug interactions.
Tetracyclins	There is experience in the treatment of acne. Adverse events are more frequent with minocycline than with doxycycline	Minocycline: skin pigmentation, drug-induced lupus (53 cases per 100,000 treatments) and hepatitis (1 case per 10,000 treatments and month) ²⁸⁰⁻²⁸² . Doxycycline: drug-induced photosensitivity, digestive adverse events, including esophageal ulcers and erosions.

FIG.1

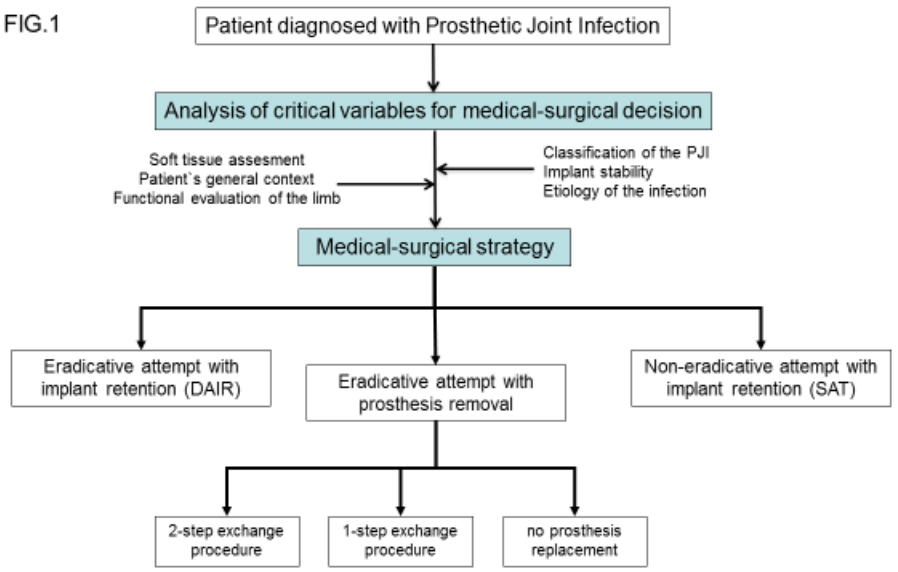


Figure 1